

A Female Child with Skin Lesions and Seizures

Case report of *Incontinentia Pigmenti*

Sana Al-Zuhaibi,¹ Anuradha Ganesh,¹ Ahmed Al-Waili,³ Faisal Al-Azri,⁴ Hashim Javad,²
*Amna Al-Futaisi²

طفلة مع آفات جلدية وحالة صرع تقرير عن حالة سلس الصباغ

سناء الزهبي، أنورادها غانيش، أحمد الوائلي، فيصل العزري، هاشم جواد، أمنا الفطيسي

الملخص: سلس الصباغ مرض وراثي نادر مرتبط بالجنس وذو وراثية سائدة. المرض يصيب أجهزة متعددة متعلقة بالأديم الظاهر العصبي تشمل الجلد والعين والشعر والأظافر والأسنان والجهاز العصبي المركزي. عادة ما يكون المرض قاتلا عند الذكور. بينما يكون ذا أشكال متغيرة سريريا عند الإناث. ننشر هنا تقريرا عن حالة طفلة عمرها ستة أشهر أدخلت إلى مستشفى جامعة السلطان قابوس (سلطنة عمان) بحالة صرع حديثي الولادة مصحوبة بأفات جلدية ناقصة الصباغ أو مفرطته ولديها مظاهر عينية وعصبية متعددة غير طبيعية نوقشت في هذا التقرير.

مفتاح الكلمات: سلس الصباغ، صرع، عينية، نقص الميلانين لايتو، مرض عصبي، تقرير حالة عمان

ABSTRACT: *Incontinentia Pigmenti (IP)*, (OMIM # 308300), is a rare X-linked dominant condition. It is a multisystemic disease with neuroectodermal findings involving the skin, eyes, hair, nails, teeth, and central nervous system. It is usually lethal in males; the disease has variable expression in an affected female. We report the case of a 6 month old girl who presented at Sultan Qaboos University Hospital, Oman, with neonatal seizures and hypopigmented/hyperpigmented skin lesions. She had multiple ophthalmic abnormalities and neurological manifestations which are discussed in this report.

Keywords: *Incontinentia Pigmenti (IP)*; Seizures; Ophthalmic; Hypomelanosis of Ito; Neurologic diseases; Case report; Oman.

INCONTINENTIA PIGMENTI (IP) TYPE 2, ALSO known as Bloch-Sulzberger syndrome, is an inherited multisystem neurocutaneous disorder with a low incidence (1% of all neurocutaneous disorders).¹ It is an X-linked dominant condition dominant inheritance. The disease is lethal in males, except in rare cases of somatic mosaicism, or mutations in *IKBKG*, and when the condition occurs in patients with Klinefelter syndrome.^{2,3} Typical skin lesions are seen in 100% of (IP) patients.² Other manifestations include dental (90%), skeletal (40%), central nervous system (CNS) (40-50%) and ocular (35%) conditions.^{4,5}

Patients with IP frequently have systemic involvement, similar to the involvement in patients with hypomelanosis of Ito, including CNS manifestations. In patients with IP, cutaneous lesions undergo three stages, which may overlap.⁶

In this report, we discuss the dermatologic, neurological and ophthalmologic findings of a 6 month old female who presented with early onset

neonatal seizures and displayed hypopigmented/hyperpigmented skin lesions. In addition, this child had characteristic ophthalmologic findings.

Case Report

This 6 month old girl was born by spontaneous vaginal delivery to healthy non-consanguineous parents with two normal sons. She was referred to Sultan Qaboos University Hospital (SQUH), Oman, from a peripheral hospital for evaluation of abnormal skin lesions and seizures.

She was reported to have had hyper/hypopigmented skin lesions all over her body except the face since she was 6 days old. The skin lesions were noted to be of linear pattern over the upper and lower limbs and of a whorled pattern over the anterior and posterior chest wall. The mother denied the presence of any skin lesion at birth. Her examination showed evidence of hypotonia and

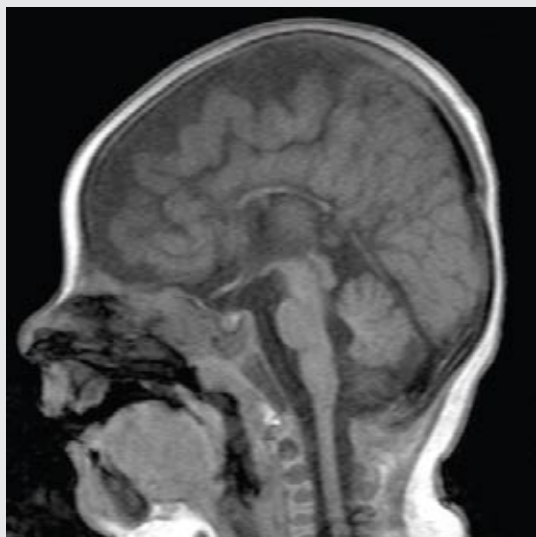

Figure 1a: Magnetic resonance imaging scan: Sag T1W SE, midline. There is hypoplasia of the corpus callosum. Optic chiasm, pituitary gland and midbrain are grossly normal.

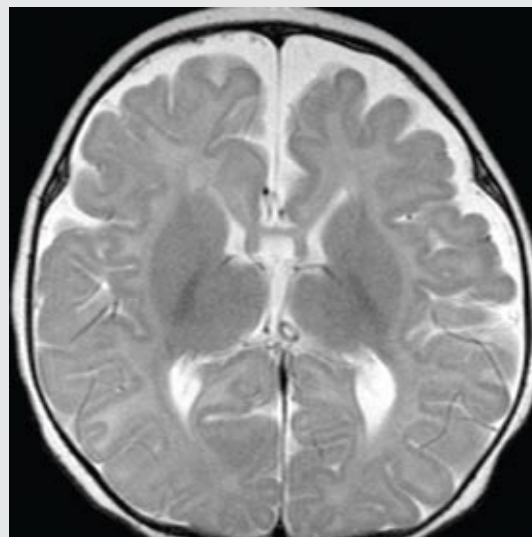


Figure 1b: Magnetic resonance imaging scan: axial T2W SE at level of basal ganglia. There is bilateral hyperintense signal abnormality in the periventricular white matter associated with brain atrophy. No imaging findings of acute ischemia or cortical necrosis

mild developmental delay with microcephaly where her head circumference was significantly below the third percentile for age. Her weight was below the third percentile, but her height was normal for age. Her tone was mildly decreased with normal reflexes and positive Babinski reflex. She had a normal visual following, but was not able to respond to sound clinically. Other systemic examinations were normal.

The child developed clonic seizures at the age of 3.5 months and was commenced on oral phenobarbitone with good seizure control. The computed tomography (CT) scan of the brain (performed at a peripheral hospital) showed atrophy of the frontal horns with corpus callosum agenesis. A chromosomal study showed a normal female karyotype.

At SQUH, a magnetic resonance imaging (MRI) of the brain showed hypoplasia of the corpus callosum and hypomyelination with periventricular white matter hyperintense signal abnormalities [Figures 1a and 1b]. Electrophysiological testing showed positive visual evoked potential (VEP) responses using a flash stimulation, but negative responses for brain stem auditory evoked potentials (BAEP).

An ophthalmologic evaluation was performed at the age of 5 months. The child was able to follow and fixate with both eyes. There was no obvious nystagmus, ocular deviation or ptosis. Further

examination under anaesthesia revealed bilateral inferior superficial epithelial corneal erosions; there were no stromal infiltrates or any increase in corneal thickness. The corneal size was normal for age in both eyes. She had a bilateral mild form of persistent pupillary membrane. She had a normal red reflex and normal reacting pupils with no evidence of any relative afferent defect. The intraocular pressure was 24mmHg in both eyes. No major refractive error was noted. A dilated fundus examination showed a large optic disc cup (disc cup ratio of 0.8 in both eyes). There were diffuse non-specific retinal pigment epithelial changes. The peripheral retinal examination revealed areas of fibrovascular proliferation with no evidence of retinal traction or detachment [Figures 2a and 2b]. The child was started on latanoprost 0.05% eye drops q.h.s. in both eyes with regular follow-ups at the eye clinic. Histological studies of the skin lesions and genetic studies were scheduled; unfortunately, the child died from *status epilepticus* at a peripheral hospital before these studies could be undertaken.

Discussion

IP is characterized by abnormalities of the tissues and organs embryologically derived from ectoderm and neuroectoderm.⁴ The diagnosis of *IP* is made on

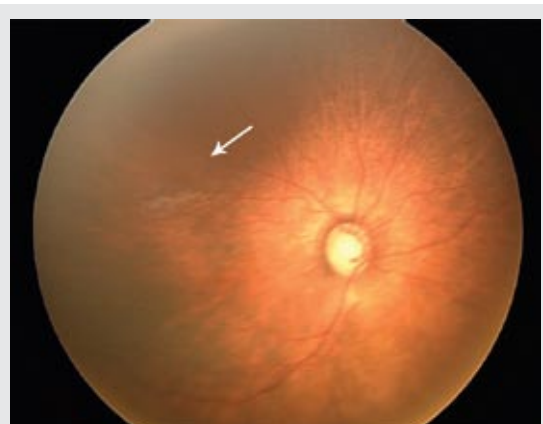


Figure 2a: RetCam fundus photo of the right eye showing large disc cupping and epiretinal pseudogliosis superior to the fovea (arrow)

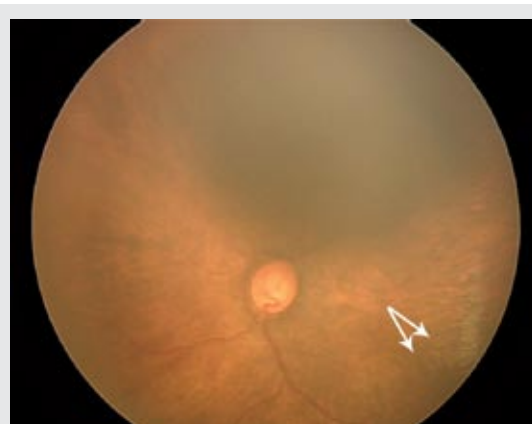

Figure 2b: RetCam fundus photo of the right eye showing large disc cupping and epiretinal pseudogliosis superior to the fovea (arrow)

clinical grounds aided by histological confirmation. The skin lesions may follow the Blaschko lines and the initial appearance of skin lesions can be seen immediately after birth or early during the neonatal period. Timely recognition of *IP* by pediatricians and dermatologists is therefore crucial. *IP* overlaps with hypomelanosis of Ito, which is a syndrome with hypopigmented whorls of the skin along the Blaschko lines, especially when it presents at the stage of skin hypopigmentation. Chromosomal mosaicism is believed to be the reason that hypomelanosis of Ito is so varied in phenotype. Certain genes, namely, those on 9q33-qter, 15q11-q13, and Xp11, have been implicated in hypomelanosis of Ito; however, no consensus exists about the identity of the hypomelanosis of Ito gene.^{5,6}

In around 40-50% of *IP* cases, there may be neurological problems such as seizures, spasticity, or mental retardation.¹ Seizure can be the first manifestation of the disease.² Abnormal tooth eruption, malformed tooth crowns, and patchy alopecia are commonly seen. Retinal dysplasia can sometimes lead to visual problems.

The diagnosis of *IP* is also aided by family history and a history of miscarriages of the male gender as the disease is prenatally lethal in males. The disease is caused by a genomic rearrangement of the gene for NEMO, or nuclear factor kappa B essential modulator (IKBKG-IKK gamma). The defect in the X chromosome is proximal to the gene for factor VIII at Xq28.^{7,8} Although this child was the first affected in her family with two normal male siblings and no previous miscarriages in the family, she had hypopigmented/hyperpigmented

lesions suggestive of the disease. Initially, the diagnosis was not entertained, despite the skin manifestations, until her presentation with partial seizures. The possibility of hypomelanosis of Ito diagnosis was also kept in mind though further evidence of neurological involvement and the eye manifestations were suggestive of *IP*.

The skin lesions in *IP* manifest in stages that evolve sequentially.⁷ The onset and duration of each stage vary among individuals; not all individuals experience all four stages.¹ Typically four dermatological stages are seen: 1) the bullous stage; early blistering with eosinophilia; 2) the verrucous stage: eruption of hyperkeratotic lesions; 3) the hyperpigmentation stage: hyperpigmentation along the lines of Blaschko and, finally, 4) the atretic stage: dermal scarring. In the vast majority of cases, the onset of skin changes is before 6 weeks of age.¹ Our patient had the third stage which was not preceded by the first or second stages. The differential diagnosis of patients presenting with stage 3 and 4 skin lesions includes: hypomelanosis of Ito; *IP achromians*; focal dermal hypoplasia syndrome (Goltz syndrome) and X-linked dominant *chondrodysplasia punctata*.

In *IP*, variable clinical expressions of CNS involvement are seen. They include epilepsy, mental retardation, hemiparesis, spasticity, microcephaly, and cerebellar ataxia.⁵ The pathogenesis of the CNS lesion in *IP* remains unclear.^{9,10,11} Recent brain-imaging techniques, such as MRI and magnetic resonance angiogram (MRA), have provided a better understanding of the nature of the CNS pathology. These imaging studies have demonstrated scattered cortical neuronal and white-matter necrosis,

hypoplasia of the corpus callosum, periventricular white-matter cystic lesions, neuronal heterotopia, and cerebral atrophy.^{12, 13}

Our patient had evidence of hypoplasia of the corpus callosum and decreased myelination of the white matter and, clinically, both seizures and developmental delay. The presence of CNS involvement, such as seizures, in the neonatal period is a poor prognostic sign.^{4, 6, 7}

Ocular abnormalities occur in 35% or more of patients and 19% are at risk of severe visual loss in one or both eyes.^{14, 15} A wide range of ophthalmologic findings are seen in patients with *IP*.⁷ The commonest reported are strabismus in 18.2% and a retrolental mass or retinal pseudoglioma in 15.4%.

There are previous reported cases in literature of multiple corneal abnormalities including megalocornea, corneal oedema, band keratopathy, bullus keratopathy, variable corneal epithelial and stromal changes and iridocorneal attachments.¹⁰ The corneal findings in this child were superficial punctuate epithelial erosion and features suggestive of an inflammatory noninfectious process.

The posterior segment findings may include multiple retinovascular abnormalities (such as retinal vascular tortuosity, macular capillary dropout, peripheral arteriovenous shunts, retinal neovascularisation, and vitreous haemorrhage). Subsequently, preretinal fibrosis, pseudoglioma and traction retinal detachment can result.¹⁴ This child had findings suggestive of what looked like pseudogliomas in both eyes [Figures 2a and 2b] and peripheral fibrovascular lesions OU with no evidence of retinal traction.

Holstrom proposed a scheme for following patients with *IP* and eye manifestations. They recommended that eyes should be examined soon after birth, and then at least monthly for three to four months, at three-month intervals for one year, and twice yearly up to three years. They also recommended that the frequency of examinations should be increased in children with retinal disease. If, at three years of age, no abnormalities, refractive errors or strabismus are found, they state that the follow-up can cease.¹⁶

During the ophthalmic follow-up, visual functions should be assessed by both clinical and electrophysiological measures including VEP and electroretinography (ERG).^{16, 17} Any significant refractive errors should be corrected and amblyopia

therapy as well as strabismus treatment should be provided.^{18, 19} Cryotherapy or laser photocoagulation should be applied for active peripheral retinal abnormalities and tractional retinal detachment should be treated surgically.

Conclusion

In summary, *IP* or Bloch-Sulzberger syndrome is a rare X-linked dominant syndrome. It has multisystemic involvement that includes the skin, central nervous system and eyes. In neurocutaneous syndromes, multidisciplinary care with periodic consultations with a paediatric ophthalmologist, neurologist and other specialists depending on the associated anomalies are essential. The differentiation between hypomelanosis of Ito and *IP* can be difficult as the two disorders overlap considerably. Clinicians need to be aware of the variable manifestations of this disease for a timely and multidisciplinary management of such patients.

Acknowledgments

Thanks are due to the parents of this child who consented to publication of this report and the photos in a medical journal.

References

1. Landy SJ, Donnai D. Incontinentia Pigmenti (Bloch-Sulzberger syndrome). *J Med Genet* 1993; 30:53-9.
2. Traupe H. Functional X-chromosomal mosaicism of the skin: Rudolf Happle and the lines of Alfred Blaschko. *Am J Med Genet* 1999; 85:324-9.
3. Scheuerle AE. Male cases of Incontinentia Pigmenti: case report and review. *Am J Med Genet* 1998; 77:201-18.
4. Türkmen M, Eliaçık K, Temoçin K, Savk E, Tosun A, Dikicioğlu E. A rare cause of neonatal seizure: Incontinentia Pigmenti. *Turk J Pediatr* 2007; 49:327-30.
5. Fritz B, Kuster W, Orstavik KH, Naumova A, Spranger J, Rehder H. Pigmentary mosaicism in hypomelanosis of Ito. Further evidence for functional disomy of Xp. *Hum Genet* 1998; 103:441-9.
6. Glover MT, Brett EM, Atherton DJ. Hypomelanosis of Ito: spectrum of the disease. *J Pediatr* 1989; 115:75-80.
7. Berlin AL, Paller AS, Chan LS. Incontinentia pigmenti: a review and update on the molecular basis of pathophysiology. *J Am Acad Dermatol* 2002;

- 47:169-87.
8. Fusco F, Bardaro T, Fimiani G. Molecular analysis of the genetic defect in a large cohort of IP patients and identification of novel NEMO mutations interfering with NF-kappaB activation. *Hum Mol Genet* 2004; 13:1763-73.
 9. Nenci A, Huth M, Funteh A, Schmidt-Supprian W, Bloch D, Metzger P, *et al.* Skin lesion development in a mouse model of incontinentia pigmenti is triggered by NEMO deficiency in epidermal keratinocytes and requires TNF signaling. *Hum Mol Gene* 2006; 15:531-42.
 10. Nehal KS, PeBenito R, Orlow SJ. Analysis of 54 cases of hypopigmentation and hyperpigmentation along the lines of Blaschko. *Arch Dermatol* 1996; 132:1167-70.
 11. Cohen BA. Incontinentia pigmenti. *Neurol Clin* 1987; 5:361-77.
 12. Pascual-Castroviejo I, Roche MC, Martinez Fernández V, Perez-Romero M, Escudero RM, García-Peñas JJ, *et al.* Incontinentia pigmenti: MR demonstration of brain changes. *AJNR Am J Neuroradiol* 1994; 15:1521-7.
 13. Lee AG, Goldberg MF, Gillard JH, Barker PB, Bryan RN. Intracranial assessment of incontinentia pigmenti using magnetic resonance imaging, angiography, and spectroscopic imaging. *Arch Pediatr Adolesc Med* 1995; 149:573-80.
 14. Carney RG. Incontinentia pigmenti: A world statistical analysis. *Arch Dermatol* 1976; 112:535-42.
 15. Kasmann-Kellner B, Jurin-Bunte B, Ruprecht KW. Incontinentia pigmenti (Bloch-Sulzberger-syndrome): case report and differential diagnosis to related dermatological syndromes. *Ophthalmologica* 1999; 213:63-9.
 16. Holmstrom, G, Thoren K. Ocular manifestations of incontinentia pigmenti. *Acta Ophthalmol Scand* 2000; 78:348-53.
 17. O'Brien JE, Feingold M. Incontinentia pigmenti a longitudinal study. *Am J Child* 1985; 139:711-2.
 18. Mayer EJ, Shuttleworth GN, Greenhalgh KL. Novel corneal features in two males with incontinentia pigmenti. *Br J Ophthalmol* 2003; 87:554-6.
 19. Taylor D, Hoyt CS, Eds. *Pediatric Ophthalmology and Strabismus*, 3rd Ed. Philadelphia: WB Saunders, 2004.