

## VIPoma Crisis

### Immediate and life saving reduction of massive stool volumes on starting treatment with octreotide

\*Omayma ElShafie,<sup>1</sup> Christopher Grant,<sup>2</sup> Aisha Al-Hamdani,<sup>3</sup> Rajeev Jain,<sup>4</sup> Nicholas Woodhouse<sup>5</sup>

إنقاذ فوري لحياة شخص بتقليص كميات ضخمة من  
البراز مع بدء العلاج بعقار اكتوبروتايد

أميمة الشفيق، كريستوفر غرانت، عائشة الحمداني، راجيف جاين ونيكولاس وودهاوس

**المخلص:** ندرج هنا تقريراً لحالة طبيب ذكر عمره 57 عاماً كان يعاني من إسهال إفرازي شديد لا يستجيب للعلاج، وقد هدد حياته، ويقدر بحوالي 20 لتراً في اليوم، وأدى إلى مضاعفات عديدة منها هبوط ضغط الدم الحاد، ونقص مستوى البوتاسيوم وزيادة مستوى الكالسيوم في الدم، والفشل الكلوي الذي يتطلب غسيل الكلى، والحماض الأيضي، وتوقف القلب والتنفس لمدة 12 يوماً. استجاب المريض على الفور للجرعة الأولى من العلاج بعقار اكتوبروتايد تحت الجلد بجرعة (100) ميكروغرام كل ثمان ساعات، والتي بدأت على أساس سريري فقط قبل إجراء أي فحص. بعد يوم واحد انتفت الحاجة إلى إعطائه السوائل عن طريق الوريد، وعاد ضغط الدم إلى طبيعته. عندما يشبه في وجود ورم الغدد الصماء سريريا يمكن استخدام عقار اكتوبروتايد كما في هذه الحالة، إذ يكون منقذاً للحياة.

مفتاح الكلمات: فيبوما، إسهال، ورم البنكرياس، ورم الغدد الصماء، اكتوبروتايد، كروموغرانين (أ)، توقف القلب والتنفس، تقرير حالة، عُمان.

**ABSTRACT:** We report the case of a 57-year-old male physician who presented with a life threatening secretory and refractory diarrhoea of around 20 L/day. This was complicated by severe hypotension, hypokalaemia, hypercalcaemia, renal failure requiring dialysis, metabolic acidosis, cardiorespiratory arrest and ventilation for 12 days. His diarrhoea responded immediately to the first dose of a therapeutic trial of subcutaneous octreotide 100 mcg 8 hourly which was started on clinical grounds alone before any investigations were carried out. After one day he was extubated and his blood pressure returned to normal. When a functioning neuroendocrine tumour is suspected clinically, the use of octreotide can, as in this case, be life saving.

**Keywords:** VIPoma; Diarrhoea; Pancreatic tumour; Neuroendocrine tumour; Octreotide; Chromogranin A; Cardiopulmonary arrest; Case report; Oman

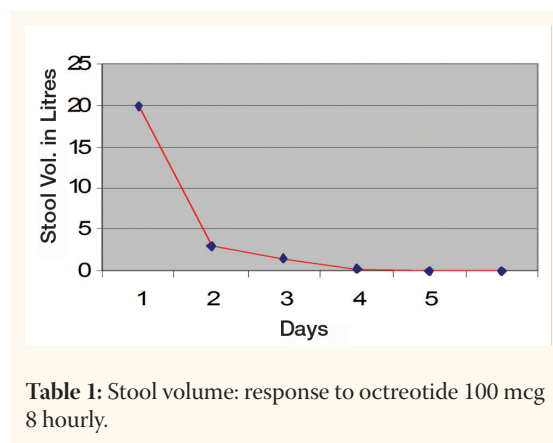
VASOACTIVE INTESTINAL POLYPEPTIDE (VIP) secreting tumours are a rare cause of chronic<sup>1</sup> or occasionally acute<sup>2</sup> secretory diarrhoea and more than 90 percent are found in the pancreas.<sup>3</sup> The tumour incidence is estimated to be one in 10 million persons per year.<sup>4</sup> They are now referred to as VIPomas; 10% of them are neural in origin and found mainly in children. The first description of an association between a pancreatic islet cell tumour and watery diarrhoea was by Priest and Alexander in 1957.<sup>5</sup> One year later, Verner and Morrison described 2 similar patients.<sup>6</sup> The association between watery diarrhoea and elevated VIP levels was reported by Bloom in 1973,<sup>7</sup> and

the clinical syndrome later confirmed when five healthy subjects developed profuse diarrhoea within 4 hours of receiving an infusion of porcine VIP.<sup>8</sup> Synonyms include the watery-diarrhoea-hypokalaemia-achlorhydria (WDHA) syndrome, the Verner-Morrison syndrome and pancreatic cholera. Functioning neuroendocrine tumours (NETs) of the pancreas may secrete a variety of different polypeptides causing a variety of different syndromes; those that secrete an excess of VIP are termed VIPomas, and usually present with chronic refractory diarrhoea and are often malignant at presentation.<sup>1</sup> Differential diagnoses include enterotoxin production by vibrio cholera and *E.coli*,

rectal vilous adenomas and bile salt entropathy.

## Case Report

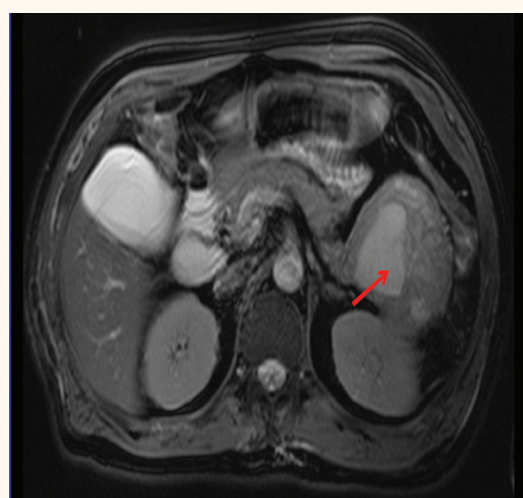
A previously fit Sri Lankan doctor presented to his local hospital with a history of well controlled diabetes mellitus for 5 years and hypertension for 15 years; his medications were valsartan, atenolol and mixtard insulin. He had noted loose watery motions for 2–3 years which he attributed to irritable bowel syndrome (IBS). Three months before being referred here, his diarrhoea had worsened and he was admitted with diabetic 'ketoacidosis' and treated with intravenous insulin (IV) and fluids. Two days later, he developed acute renal failure requiring haemodialysis for 3 days. He was treated with ciprofloxacin and discharged after two weeks. Three weeks later, he was again readmitted with profuse watery diarrhoea, confusion, vomiting and acute renal failure. Investigations revealed creatinine >300  $\mu\text{mol/L}$  (normal range [NR] 59–106), potassium 2.5 mmol/L (NR 3.5–5.0) and calcium of 3.5 mmol/L (NR 2.2–2.5). During catheter insertion for haemodialysis he vomited and aspirated his stomach contents resulting in a cardiorespiratory arrest. He was intubated and ventilated for 12 days during which time he had haemodialysis for three days, together with upper and lower gastrointestinal (GI) endoscopies which revealed a fluid filled stomach and colon with normal appearing mucosa. On his final admission to the referring hospital, he was started on ciprofloxacin, metronidazole, octreotide 50 mcg twice daily as a neuroendocrine tumour was considered as one of the differential diagnoses. After several days, however, the diarrhoea still persisted and metronidazole was added to treat possible antibiotic-associated diarrhoea. Extubation failed on at least two occasions; he was then transferred to Sultan Qaboos University Hospital by aeroplane on a ventilator, intravenous fluid and ionotropes. During the flight his blood pressure fell to 30 systolic. On arrival here, he was gravely ill with a blood pressure (BP) of 45/30 on dopamine and IV fluids. The serum creatinine was now 180  $\mu\text{mol/L}$ , potassium 2.8 mmol/L,  $\text{HCO}_3^-$  10 mmol/L (NR 22–29), Hb 19 gm/dl (n 11.5–15.0). The estimated stool volume before receiving octreotide was as much as 20 liters/day as within 12 hours he had passed 12 liters by rectal tube.



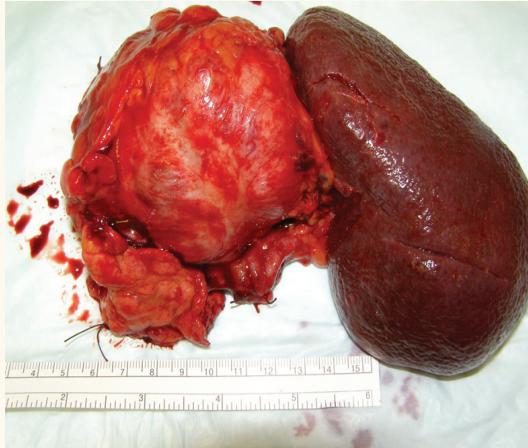
**Table 1:** Stool volume: response to octreotide 100 mcg 8 hourly.

An endocrine consultation was asked for 12 hours after his admission and based on his history, the presence of secretory odourless diarrhoea, hypokalaemia and metabolic acidosis, a clinical diagnosis of VIPoma was made. The patient was then immediately started on a therapeutic trial of octreotide, 100 mcg 8 hourly, after taking blood samples to test for VIP, chromogranin A and other hormone levels. His response was dramatic and similar to a patient treated with long acting octreotide in 1985 who also had an immediate cessation of diarrhoea.<sup>9</sup> One day later, the diarrhoea had improved substantially; he was extubated, the dopamine stopped and his BP returned to normal. By day four, his electrolyte profile was normal without any additional therapy [Table 1].

An abdominal ultrasound revealed an 8 cm mass in the left upper quadrant. Computed tomography (CT) and magnetic resonance imaging (MRI) scans



**Figure 1:** MRI scan showing pancreatic tail mass 8.2 x 7.5 cm with necrosis.

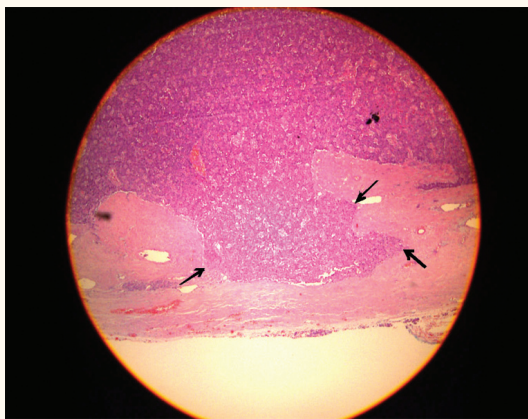


**Figure 2:** Specimen: Pancreatic tail with tumour and spleen.

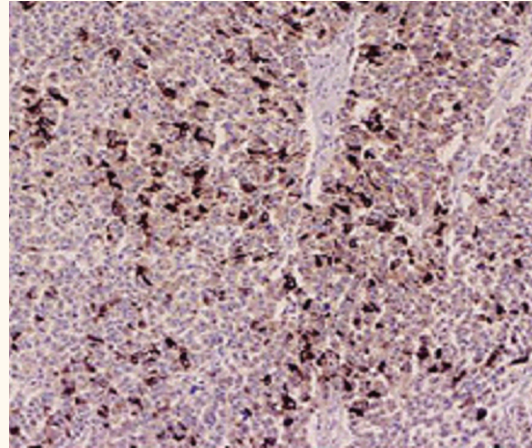
[Figure 1] of the abdomen revealed an 8.2 x 7.5 cm well encapsulated and necrotic pancreatic tail mass with no evidence of metastases. After three weeks on octreotide, the patient had gained 7 kg and felt quite normal.

On day 21, he underwent a distal pancreatectomy and splenectomy [Figure 2]. No liver, peritoneal or lymph node metastases were seen. The patient had an uneventful postoperative course and the diarrhoea has not since recurred. The octreotide was stopped four days after surgery.

Histological examination revealed a NET with partial capsular invasion [Figure 3] strongly positive for chromogranin A [Figure 4] and VIP. A minority of cells were positive for glucagon and pancreatic polypeptide (PP). The margins of the pancreas were free of tumour and the spleen was normal. Two weeks post surgery, the repeated VIP test revealed a level of 46 and chromogranin A 37, both normal



**Figure 3:** Partial capsular invasion by the tumour.



**Figure 4:** Immunohistochemistry stain positive for vasoactive intestinal polypeptide (shown as dark brown).

(Table 2). An octreoscan performed 14 weeks after surgery showed no evidence of recurrence.

## Discussion

This patient's symptoms improved immediately with the introduction of octreotide in a dose of 100 mcg thrice daily having previously failed to respond to a much smaller dose. VIP is a 28 aminoacid polypeptide which is widely distributed throughout the body and normally functions as a neurotransmitter. In the gut, VIP regulates the blood flow, smooth muscle activity, pancreatic and intestinal secretions and inhibits gastric acid production. It also stimulates intestinal water, sodium and chloride secretion, inhibits resorption and increases colonic potassium secretion.<sup>10</sup>

VIPomas are rare NETs with only 241 cases reported worldwide until 1998.<sup>11</sup> Our patient's presentation was typical with copious watery odourless diarrhoea, hypokalaemia and metabolic acidosis.<sup>12</sup> The secretory nature of the diarrhoea was confirmed by its failure to respond to fasting. Hypokalaemia results from losses in the stool and the acidosis from a combination of dehydration, hypotension and renal failure which was profound in our patient due to his massive stool volumes estimated to be up to 20 litres/day. This is much more than the usually reported volumes of 6–8 litres daily,<sup>12,13</sup> Hyperglycaemia occurs in one third of patients and results from increased hepatic glucogenolysis caused by the elevated VIP levels.<sup>4</sup> However, this was not the mechanism in our

**Table 2:** Serum peptide and electrolyte levels before (day 0) and upon discharge. CG-A: chromogranin A

Time	VIP ng/L	CG-A µg/L	K mmol/L	Crea µmol/L	HCO <sub>3</sub> mmol/L	Ca mmol/L
Admission Day 0	900	240	2.5	180	10	3.5
Post surgery Day 31	46	37	4.1	70	26	2.2
Normal range	<65	<100	>3.5	<104	>18	<2.6

patient as his insulin requirement did not change following treatment with octreotide, resection of the tumour, and normalisation of the VIP levels. The patient's hypercalcaemia resolved during treatment with octreotide and intravenous fluids excluding associated hyperparathyroidism; it was related either to dehydration induced hyperalbuminaemia or to increased bone resorption caused by excessive VIP or other peptides produced by the tumour.<sup>13</sup>

Octreotide controls symptoms and normalises VIP levels in nearly 90% of patients often with extensive metastatic disease.<sup>4</sup> Because our patient was so ill, octreotide was given as an immediate therapeutic trial before tumour localisation studies were carried out. The results were remarkable and gratifying; the diarrhea improving substantially after his first 100 mcg injection [Tables 1 and 2]. Octreotide was continued until 4 days after surgery at which time he had gained 7 kg. More than 70% of VIPoma patients present with metastatic disease.<sup>13</sup> Fortunately, this was not the case here, but his tumour was large and histologically reported as a tumour of uncertain behaviour. He will therefore be followed up with serial VIP measurements and, if indicated, further octreotide scanning.

## Conclusion

To conclude, this was a case of unexplained massive watery diarrhoea which responded immediately to octreotide treatment. Clinicians facing similar cases should prescribe a therapeutic trial of octreotide without waiting for the results of investigations as it might be life saving.

## ACKNOWLEDGEMENTS

We thank Dr Dhia Al-Layla of Sultan Qaboos Hospital, Salalah, Oman, for suggesting the possible diagnosis of a neuroendocrine tumor (VIPoma) and referring the patient to us. We also thank Professor Gordon Stamp (Royal Postgraduate Medical

School, London) for reviewing the slides and the VIP immunostaining.

## References

- Peng SY, Li JT, Liu YB, Fang Hq, Wu YL, Peng CH, et al. Diagnosis and treatment of VIPoma in China: (Case report and 31 cases review) diagnosis and treatment of VIPoma. *Pancreas* 2004; 28:93–7.
- Singh, HM, Teller T, Esrason KT, Abbas MA. VIPoma: A rare cause of acute diarrhea. *Surgical Rounds* 2007; 414:8.
- Ectors N. Pancreatic endocrine tumors: diagnosis pitfalls. *Hepatogastroenterol* 1999; 46:679.
- Friesen SR. Update on the diagnosis and treatment of rare neuroendocrine tumors. *Surg Clin North Am* 1987; 67:379.
- Priest WM, Alexander MK. Islet cell tumour of the pancreas with peptic ulceration, diarrhea and hypokalaemia. *Lancet* 1957; 273:1145–7.
- Verner JV, Morrison AB. Islet cell tumour and a syndrome of refractory watery diarrhea and hypokalaemia. *Am J Med* 1958; 25:374.
- Bloom SR, Polak JM, Pearse AGE. Vasoactive intestinal peptide and watery- diarrhoea syndrome. *Lancet* 1973; 2:14–16.
- Kane MG, O'Dorisio TM, Krejs GJ. Production of secretory diarrhoea by intravenous infusion of vasoactive intestinal polypeptide. *N Engl J Med* 1983; 309:1482–5.
- Maton PN, O'Dorisio TM, Howe BA, McArthur KE, Howard JM, Cherner JA, et al. Effect of a long-acting somatostatin analogue (SMS 201–995) in a patient with pancreatic cholera. *N Engl J Med* 1985; 312:17–21.
- Sitaraman SV, Goldfinger SE. The VIPoma syndrome; From: [http://www.uptodate.com/online/content/topic.do?topicKey=gi\\_dis/35882&selectedTitle=1%7E150&source=search\\_result](http://www.uptodate.com/online/content/topic.do?topicKey=gi_dis/35882&selectedTitle=1%7E150&source=search_result) Accessed: Aug 2010.
- Soga J, Yakuwa Y. VIPoma/diarrhoeagenic syndrome: a statistical evaluation of 241 reported cases. *J Exp Clin Cancer Res* 1998; 17:389–400.
- Amir A, Ghaferi, AA, Chojnacki KA, Long WD, Cameron JL, Yeo CJ. Pancreatic VIPomas: Subject review and one institutional experience. *J Gastrointest Surg* 2008; 12:382–93.
- Mekhjian HS, O'Dorisio TM. VIPoma syndrome. *Semin Oncol* 1987; 14:282–91.