

## Bilateral Asymmetrical Traumatic Sternoclavicular Joint Dislocations

Mohammed K. Albarrag

### خَلْعُ رَضْحِيّ ثُنَائِي الْجَانِبِ لَا مَتَنَاظِرَ لِلْمَفْصَلِ الْقَصِيّ التَّرْقَوِيّ

محمد البراق

**المخلص:** الخَلْعُ الرَضْحِيّ لِلْمَفْصَلِ الْقَصِيّ التَّرْقَوِيّ مِنْ جَانِبٍ وَاحِدٍ أَوْ جَانِبَيْنِ مِنَ الْإِصَابَاتِ النَّادِرَةِ. صَعُوبَةُ تَقْيِيمِ هَذِهِ الْحَالَةِ غَالِبًا مَا تُؤَدِّي إِلَى تَأْخِيرٍ فِي التَّشْخِصِ وَالْعِلَاجِ. تُدْرَجُ هُنَا حَالَةٌ نَادِرَةٌ مِنْ خَلْعِ رَضْحِيّ ثُنَائِي الْجَانِبِ لَا مَتَنَاظِرَ لِلْمَفْصَلِ الْقَصِيّ التَّرْقَوِيّ فِي رَجُلٍ يَبْلُغُ مِنَ الْعُمُرِ 45 عَامًا. تَمَّ عِلَاجُ الْخَلْعِ الْأَمَامِيِّ الْأَيْمَنِ فِي غُرْفَةِ الطَّوَارِئِ وَأَسْفَرَتْ عَنْ وَجُودِ عَدَمِ اسْتِقْرَارٍ مَتَبَقِيٍّ، بَيْنَمَا كَانَ الْخَلْعُ الْخَلْفِيُّ الْأَيْسَرَ بِدُونَ أَعْرَاضٍ وَلَمْ يَجْلِبِ الْإِتْبَاهَ لِمُدَّةِ سِتَّةِ أَشْهُرٍ. مِنَ الْمَهْمِ إِمْكَانِيَّةُ تَشْخِصِ وَعِلَاجِ مِثْلِ هَذِهِ الْحَالَاتِ مِنْ قِبَلِ الْأَطِبَّاءِ الْعَامِلِينَ فِي صَالَةِ الطَّوَارِئِ وَجِرَاحِي الْعِظَامِ لِتَكُونَ قَادِرَةً تَحْدِيدَ وَعِلَاجِ هَذِهِ الْحَالَةِ. وَيَنْبَغِي تَقْيِيمَ جَمِيعِ الْمَرْضَى الْمَشْتَبِهَةِ بِإِصَابَتِهِمْ بِخَلْعِ الْمَفْصَلِ الْقَصِيّ التَّرْقَوِيّ فِي الْجِهَتَيْنِ بِوَسْاطَةِ التَّصْوِيرِ الْمَقْطَعِيِّ الْخَوْسَبِ لِلتَّأَكُّدِ مِنَ التَّشْخِصِ وَلِتَقْيِيمِ حَالَةِ الْمَفْصَلَيْنِ. الْخَلْعُ الْخَلْفِيُّ لِلْمَفْصَلِ الْقَصِيّ التَّرْقَوِيّ قَدْ يَكُونُ إِصَابَةً قَاتِلَةً، وَيَنْبَغِي أَلَّا يُغْفَلَ بِسَبَبِ وَجُودِ إِصَابَاتٍ أُخْرَى. التَّدْخُلُ الْجِرَاحِيُّ غَالِبًا مَا يَكُونُ ضَرُورِيًّا فِي الْحَالَاتِ الْحَادَّةِ وَالْقَدِيمَةِ.

**مفتاح الكلمات:** كتف، مفصل قصي ترقوي، خلع، طوارئ، تقرير حالة؛ المملكة العربية السعودية.

**ABSTRACT:** Unilateral and bilateral sternoclavicular joint (SCJ) dislocations are rare injuries. The difficulty in assessing this condition often leads to delay in diagnosis and treatment. We report a rare case of bilateral asymmetrical traumatic SCJ dislocations in a 45-year-old male. The right anterior SCJ dislocation was reduced in the emergency room (ER) and resulted in residual instability. The left posterior SCJ dislocation was asymptomatic and unnoticed for six months. It is important for ER physicians and orthopaedic surgeons to be able identify and treat this condition. All suspected SCJ dislocations should be evaluated by computed tomography (CT) scan for confirmation of the diagnosis and evaluation of both SCJs. Posterior SCJ dislocation is a potentially fatal injury and should not be overlooked due to the presence of other injuries. Surgical intervention is often necessary in acute and old cases.

**Keywords:** Shoulder; Sternoclavicular joint; Dislocations; Emergency; Case report; Saudi Arabia.

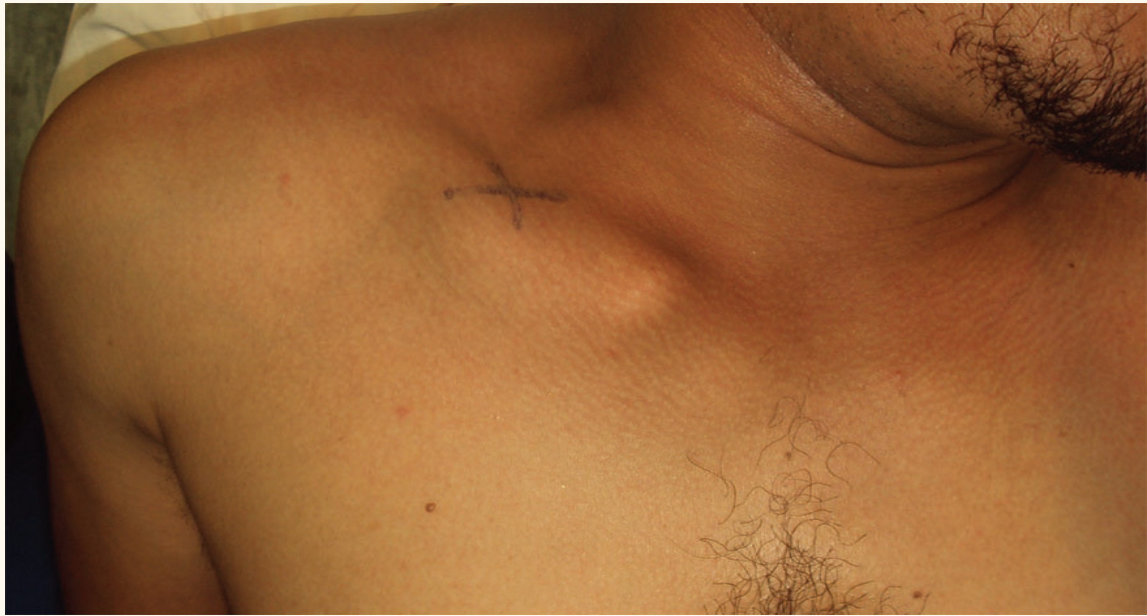**T**RAUMATIC BILATERAL STERNOCLAVICULAR joint (SCJ) dislocation is a very rare injury, as 95% are unilateral. Anterior SCJ dislocation represents 3% of all injuries of the shoulder girdle and comprises 1% of all joint dislocations;<sup>1</sup> a ratio of approximately 20 anterior dislocations to each posterior was given in a large series.<sup>2</sup> In another study, the frequency of posterior SCJ dislocations represents 0.019% of all shoulder injuries.<sup>3</sup>

The diagnosis of this injury requires good evaluation of the patient in the emergency room (ER). A chest X-ray is not always helpful but, in suspected cases, a computed tomography (CT)

scan of the chest with a 3-D reconstruction has the advantage of showing an obscure injury of the SCJ.<sup>4</sup>

Treatment of an anterior SCJ dislocation is close reduction under general anaesthesia or intravenous sedation by direct pressure over the medial portion of the clavicle of a supine patient with a solid pad placed between the shoulders. This injury is often unstable after close reduction with the risk of recurrent instability, but this rarely results in a functional deficit.<sup>5</sup>

A posterior SCJ dislocation is potentially life-threatening, with the possibility of concomitant injuries to thoracic structures such as the trachea, oesophagus, or great vessels. Acute surgical



**Figure 1:** Clinical image of the patient shows the deformity of the anterior dislocation of the right sternoclavicular joint (SCJ) and the absence of the normal shape of the left SCJ.

intervention is often necessary by close reduction, excision and reconstruction under general anaesthesia.

## Case Report

A 45-year-old healthy male soldier was involved in a motor vehicle accident in August 2006. He was the driver, was not wearing a seat belt and, when he fell asleep, hit a big truck in front of him. The patient sustained blunt chest trauma with transient loss of consciousness, and multiple abrasions to the face and body, mainly on the left shoulder and forearm.

When this patient was seen in the ER, he was stable but drowsy. The chest X-ray was normal. The patient, however, complained of chest pain without dyspnoea, haemoptysis, or dysphagia. The deformity of anterior SCJ dislocation was obvious on the right side for which a successful trial of close reduction was done in the ER under intravenous sedation, and the limb was held in a shoulder immobiliser. A CT scan of the chest was not done for the initial evaluation.

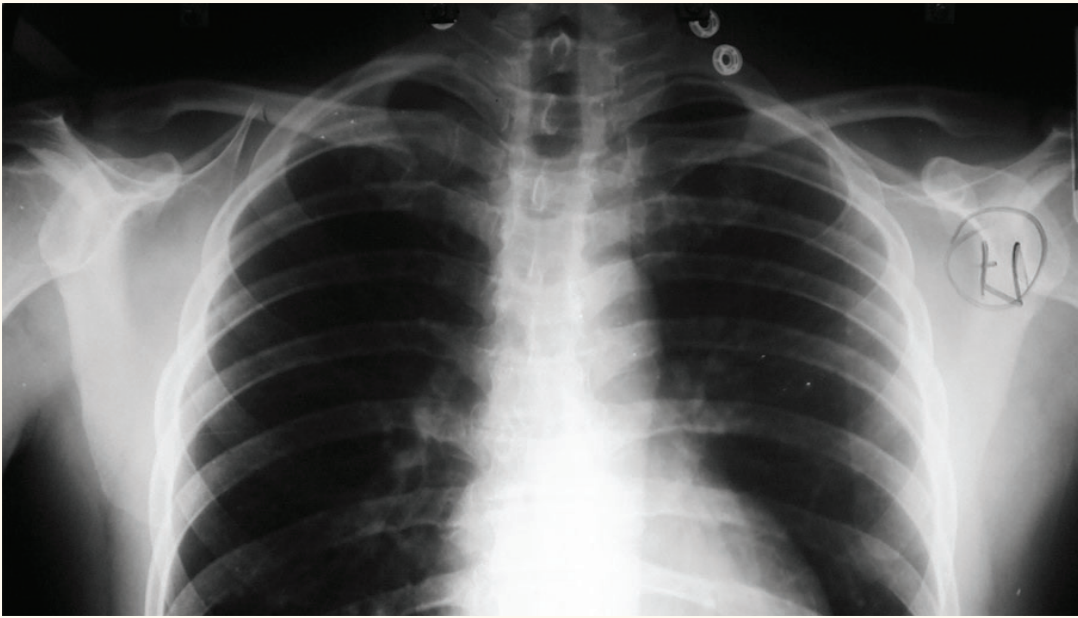
Three weeks later the patient noticed recurrence of the deformity and instability in the right SCJ, which was treated conservatively by immobilisation, non-steroidal anti-inflammatory drugs, and physiotherapy. The patient had split skin grafting for the large abrasions. At a 6-month follow-up, the

patient was complaining of a prominent medial end of the right clavicle, instability and discomfort.

On examination, the patient was a moderately-built healthy male with good air entry of the chest, no abnormal sounds, no hoarseness of voice, and no tenderness over the SCJs. The right SCJ was prominent, mobile and unstable [Figure1]. Both shoulders had full range of movement with normal sensation and power in the upper limbs.

Radiological evaluations included a chest X-ray, which was interpreted as normal and did not illustrate the magnitude of the injury [Figure 2]. A CT scan of the chest with 3-D reconstruction showed anterior dislocation of the SCJ on the right side as well as an unexpected and potentially life-threatening left SCJ dislocation in the superior and posterior direction without compression of the mediastinum [Figure 3]. The left posterior SCJ dislocation was overlooked at the beginning and the patient was surprisingly asymptomatic.

Surgical intervention was discussed and advocated but the patient preferred to continue with conservative management, including physiotherapy and analgesics. He was followed up for three years and was without neurovascular symptoms or disability at the final follow-up.



**Figure 2:** Chest X-ray showing both clavicles on the same level with no obvious sternoclavicular joint injury.

## Discussion

Unilateral and bilateral traumatic anterior SCJ dislocations have rarely been reported.<sup>2,4</sup> Unilateral and bilateral traumatic posterior SCJ dislocations are even less common;<sup>3,6</sup> however, similar cases with asymmetrical presternal and retrosternal SCJ dislocations, (for example, the reports by Hotchkiss in 1896, and Stapelmohr in 1932) have been mentioned in a historical review.<sup>7</sup>

The SCJ is stabilised by a joint capsule, by the anterior and posterior sternoclavicular and interclavicular ligaments, and particularly by the costoclavicular ligament. The posterior structures are stronger than the anterior and this is why posterior SCJ dislocations are rarer than anterior dislocations. Good knowledge of the anatomy of the SCJ and its variations is important to identify the pathology, as more than 10% of asymptomatic patients show substantial asymmetry in SCJs.<sup>8</sup>

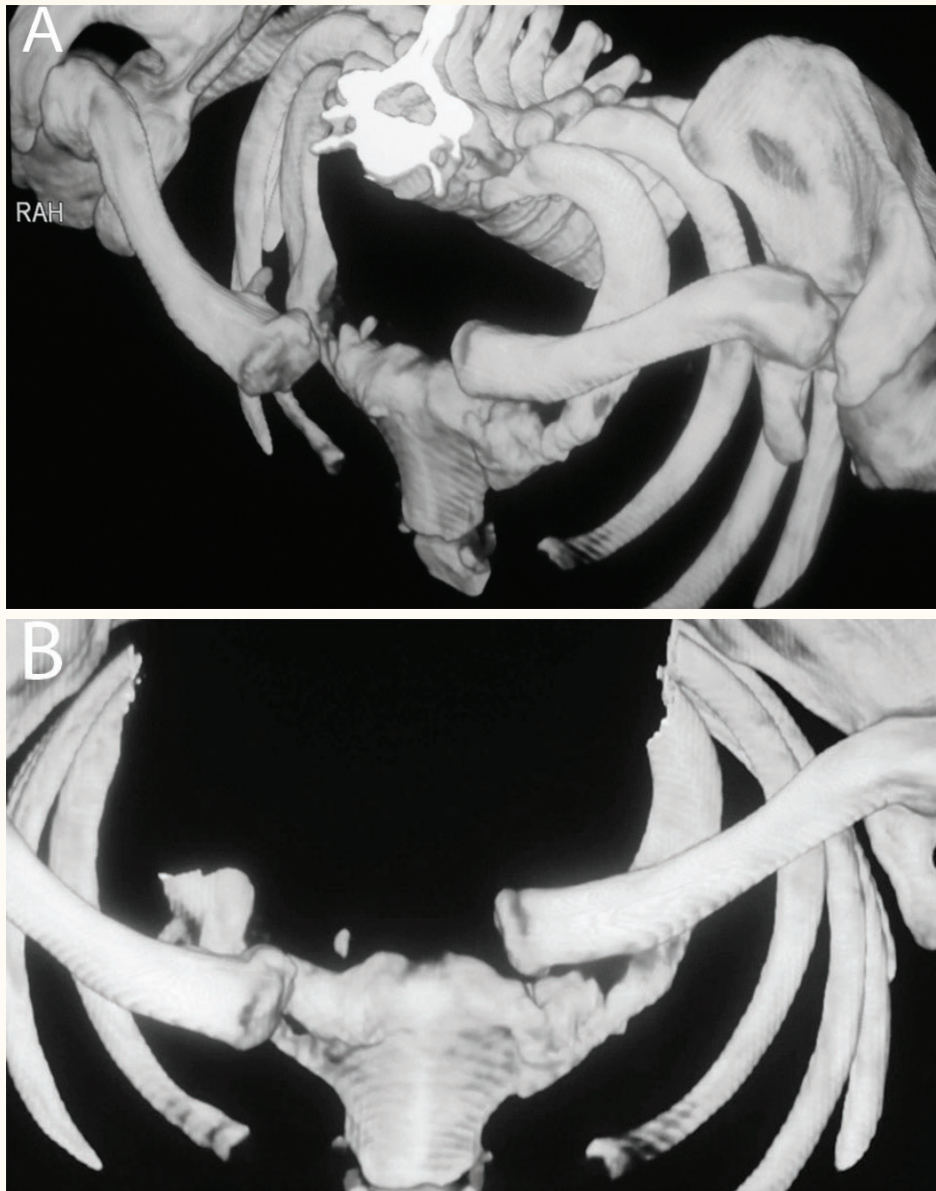
This injury commonly results from high-energy trauma, such as motor vehicle crashes, sport injuries, or falls from a height.<sup>2</sup> Asymmetrical SCJ dislocation is an extremely unusual injury which could be explained by the indirect mechanism of injury to produce anterior and posterior dislocations with forces applied to the shoulder girdle from the anterolateral and posterolateral directions, respectively. A posterior SCJ dislocation may also occur from a direct force applied to the medial end

of the clavicle.

The key to diagnosis is a detailed patient history and physical examination. Nevertheless, before CT scan evaluation became possible, such injuries were often discovered post-mortem.<sup>9</sup> The delay in the diagnosis of the posterior SCJ dislocation on the left side occurred because of the slight deformity, and the presence of other injuries in the left forearm with the right anterior SCJ dislocation, which drew the attention of the treating team. The absence of mediastinal compression symptoms which include shortness of breath, hoarseness, and dysphagia was another reason the potentially fatal posterior SCJ dislocation on the left side was overlooked.

The literature supports conservative treatment for most patients with chronic anterior sternoclavicular instability. Those patients with ongoing disability may be candidates for joint reconstruction. Patients with posterior dislocations are typically stable after reduction, but require surgery if they redislocate or if there is ongoing symptomatic instability.<sup>10</sup> However, a neglected or incompletely reduced retrosternal dislocation constitutes a constant danger to the patient.<sup>7</sup>

An optimal, standardised operative procedure has not been established because of the small number of cases. Many surgical procedures have been advocated to treat SCJ dislocations such as Kirschner wires or Steinmann pin fixation; however, these are now contraindicated by the



**Figure 3:** (A) A 3-D chest computed tomography scan which clearly shows the right anterior and left posterior sternoclavicular joint dislocations. (B) A 3-D chest computed tomography scan with a superior view of the dislocated right anterior and left posterior sternoclavicular joints.

potential for migration into vital structures.<sup>11</sup> The use of more stable implants, such as wire sutures, or using polydioxane (PDS) cords or custom-made plates is possible, although these implants have a substantial risk of intrathoracic migration if breakage or loosening occurs.<sup>12</sup> Arthrodesis of the SCJ is also contraindicated because of the marked restriction in shoulder movement which it produces.<sup>13</sup> Resection of approximately 1 to 2 cm of the medial clavicle is an alternative procedure when there is no residual soft tissue attached to the medial clavicle, but the outcome of resectioning is poor, with painful restricted movement of the shoulder,

and limited abduction.<sup>14</sup> The best outcomes were shown with the use of the semitendinosus tendon graft in a figure-of-eight fashion through drill holes in the sternum and manubrium.<sup>10,15</sup>

## Conclusion

SCJ dislocations are rare injuries. Bilateral SCJ dislocation is extremely rare and can appear symmetrically or asymmetrically. A careful patient history and examination is invaluable. Additionally, a 3-D CT scan should be done to confirm the diagnosis, to evaluate the extent of the injury, and to

look for bilateral involvement. Avoiding improper patient selection and surgical complications are two cornerstones of the management of this problem. Conservative treatment for chronic anterior SCJ dislocation will produce satisfactory results. Potentially life-threatening complications can occur due to acute posterior SCJ dislocation if not diagnosed and treated early. Old and neglected posterior SCJs should be operated upon because of the constant risk of late complications.

## References

1. Renfree KJ, Wright TW. Anatomy and biomechanics of the acromioclavicular and sternoclavicular joints. *Clin Sports Med* 2003; 22:219–37.
2. Nettles JL, Linscheid R. Sternoclavicular dislocations. *J Trauma* 1968; 8:158–64.
3. Camara ES, Bousso A, Tall M, Sy MH. Posterior sternoclavicular dislocations. *Eur J Orthop Surg Traumatol* 2009; 19:7–9.
4. Chien LC, Hsu IL, Tsai MC, Lo CJ. Bilateral anterior sternoclavicular dislocation. *J Trauma* 2009; 66:1504.
5. Yeh GL, Williams GR, Jr. Conservative management of sternoclavicular injuries. *Orthop Clin North Am* 2000; 31:189–203.
6. Baumann M, Vogel T, Weise K, Muratore T, Trobisch P. Bilateral posterior sternoclavicular dislocation. *Orthopedics* 2010; 33:510.
7. Tyer HDD, Sturrock WDS, McCallow F. Retrosternal dislocation of the clavicle. *J Bone Joint Surg Br* 1963; 45-B:132–7.
8. Tuscano D, Banerjee S, Terk MR. Variations in normal sternoclavicular joints; A retrospective study to quantify SCJ asymmetry. *Skeletal Radiol* 2009; 38:997–1001.
9. Rajaratnam S, Kerins M, Apthorp L. Posterior dislocation of the sternoclavicular joint: A case report and review of the clinical anatomy of the region. *Clin Anat* 2002; 15:108–11.
10. Thut D, Hergan D, Dukas A, Day M, Sherman OH. Sternoclavicular joint reconstruction--A systematic review. *Bull NYU Hosp Jt Dis* 2011; 69:128–35.
11. Liu HP, Chang CH, Lin PJ, Chu JJ, Hsieh HC, Chang JB, et al. Pulmonary artery perforation after Kirschner wire migration: Case report and review of the literature. *J Trauma* 1993; 34:154–6.
12. Franck WM, Jannasch O, Siassi M, Hennig FF. Balsaer plate stabilization: an alternate therapy for traumatic sternoclavicular instability. *J Shoulder Elbow Surg* 2003; 12:276–81.
13. Robinson CM, Jenkins PJ, Markham PE, Beggs I. Disorders of the sternoclavicular joint. *J Bone Joint Surg Br* 2008; 90-B:685–96.
14. Eskola A, Vainionpaa S, Vastamaki M, Slätis P, Rokkanen P. Operation for old sternoclavicular dislocation: Results in 12 cases. *J Bone Joint Surg Br* 1989; 71B:63–5.
15. Bae DS, Kocher MS. Chronic recurrent anterior sternoclavicular joint instability: results of surgical management. *J Pediatr Orthop* 2006; 26:71–4.