

Sporadic Lateral Ventricular Hemangioblastoma presenting with Intraventricular and Subarachnoid Haemorrhage

*Mahasen Al-Najar, Azmy Al-Hadidy, Alaa Saleh, Ahmad Al-Tamimi, Asaad Al-Darawish, Fatima Obeidat

ورم أرومي وعائي فردي في البطين الوحشي ظهر بنزف داخل البطين و نزف تحت العنكبوتية

محاسن النجار، عزمي الحديدي، ألاء صالح، أحمد التميمي، أسعد الدراويش، فاطمة عبيدات

المخلص: تم الإبلاغ عن عدد قليل من حالات الورم الأرومي الوعائي داخل البطين في الأدب الطبي إما بشكل فردي أو مرتبطاً بمرض فون هيبيل لينداوز. فضلاً عن ذلك، فإن حدوث النزف البطيني من ذلك الورم يبدو استثنائياً. نعرض هنا حالة نادرة لورم أرومي وعائي فردي في البطين الوحشي الأيمن ظهر بشكل نزف في داخل الورم و داخل البطين، بالإضافة إلى وجود بقع حداد سطحية متعددة داخل الجمجمة و التي تشير إلى حدوث نزف تحت العنكبوتية أيضاً. لم يتم الإبلاغ عن مثل ذلك الارتباط من قبل. إن إيجاد ورم داخل البطين مع وجود نزف بطيني مع أو بدون نزف تحت العنكبوتية، سوف يجعلنا نضع الورم الأرومي الوعائي ضمن القائمة التشخيصية، خاصة إذا لم تطابق المظاهر الإشعاعية الأورام الأخرى الأكثر شيوعاً.

ABSTRACT: Intraventricular hemangioblastoma (HB) is very rare; few cases of intraventricular HB have been reported in the literature, either sporadically or in association with von Hippel-Lindau disease. Furthermore, the incidence of ventricular haemorrhage from HB seems to be uncommon. We report a unique case of sporadic HB of the right lateral ventricle presenting with intratumoural and intraventricular haemorrhage in addition to multifocal intracranial superficial siderosis, indicating the presence of a subarachnoid haemorrhage (SAH) as well. Such a combination has not been reported before. In the future, the detection of an intraventricular mass in association with ventricular haemorrhage, with or without SAH, should include HB as a differential diagnosis, particularly when the imaging appearances are not typical of the more common intraventricular tumours.

Keywords: Hemangioblastoma; Lateral Ventricle; Subarachnoid Hemorrhage; von Hippel-Lindau Disease; Case Report; Jordan.

HEMANGIOBLASTOMA (HB) OF THE central nervous system occurs usually in the infratentorial structures, but it may occur in supratentorial structures. However, HB of the lateral ventricle is very rare. The first case of intraventricular HB was incidentally discovered during a postmortem examination and, since then, only a few other cases have been reported.¹ Spontaneous haemorrhage is so uncommon among HB cases that, when it happens, it usually presents with a subarachnoid haemorrhage (SAH) or intracerebral bleeding. An intraventricular haemorrhage from HB seems to be rare, and only one case of intraventricular HB was previously

reported to cause direct haemorrhage into the ventricular system.² We believe that our case is the second one worldwide.

Case Report

A 70-year-old man presented to the emergency room with severe headache, vomiting and dizziness. He had had no seizures, changes in level of consciousness, fever, or a history of trauma. The patient had had recurrent headaches during the previous 3 months which were attributed to uncontrolled hypertension. His blood pressure was 150/70 mmHg. Other vital signs were stable and a

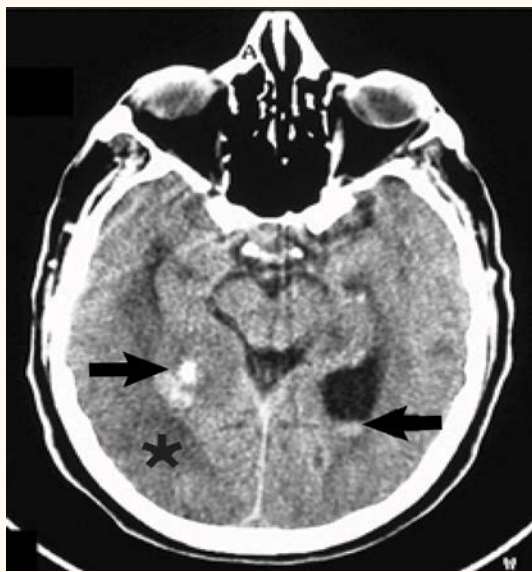


Figure 1: Axial non-enhanced brain computed tomography scan showing the haemorrhagic tumoral mass occupying the right occipital horn (black arrow, left) with surrounding vasogenic oedema (black star). A blood level is seen in the left one (black arrow, right).

physical examination was unremarkable.

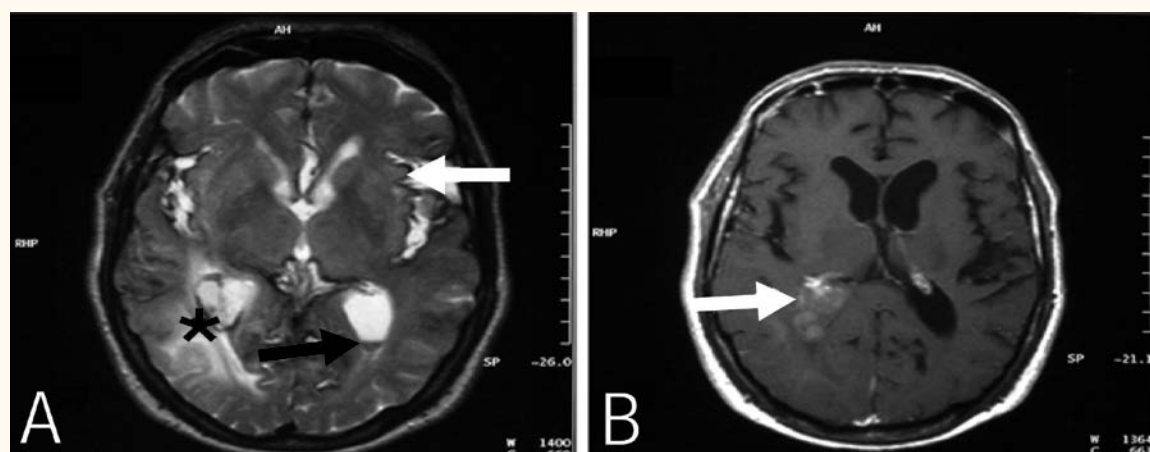
Neurological examinations revealed disorientation and an unsteady gait in addition to left upper motor neuron facial palsy and left-sided hemiparesis. Laboratory investigations, including complete blood count, coagulation profile, and liver and renal function tests were all normal, with a haemoglobin level of 12.5 g/dl. A fundoscopic examination was also normal.

An unenhanced computed tomography (CT) scan showed evidence of haemorrhage in the right ventricular trigone and occipital horn,

surrounded by vasogenic oedema with suspicion of an underlying mass lesion. A blood level was also noted in the left occipital horn [Figure 1]. Magnetic resonance imaging (MRI) confirmed the presence of a mass lesion in the trigone and occipital horn of the right lateral ventricle, which appeared isointense to grey matter on T1-weighted images and markedly hyperintense on T2-weighted and fluid attenuated inversion recovery (FLAIR) images. These images also showed internal haemorrhagic *foci*. Intraventricular bleeding was again noted in addition to multifocal superficial siderosis particularly around the brainstem and in both Sylvian fissures [Figure 2A]. This was best visualised on the gradient-recalled echo images (GRE), indicating the presence of SAH.

Gadolinium-enhanced T1-weighted images demonstrated a solitary, solid, mildly heterogeneously enhancing intraventricular mass about 3.3 cm in diameter [Figure 2B]. The approximate volume of this lesion was 12.4 cm³ which was calculated by a modified ellipsoid formula (length × width × height × 0.5). Magnetic resonance angiography did not show any abnormal vascularity. Four-vessel conventional angiography was also normal.

A frameless stereotactic brain biopsy was performed and a histopathologic examination showed HB. The tumour cells were arranged in nests separated by fine fibrovascular *septae* with occasional mitotic figures and bizarre *nuclei*. Based on this result, the patient underwent an abdominal ultrasound examination to check for possible



Figures 2 A & B. A: Axial T2-weighted image. Note the superficial siderosis, particularly in the Sylvian fissures (white arrow) in addition to the hemosiderin rim around the tumour (black star). Again note the blood level in the left occipital horn (black arrow). B: Contrast enhanced T1-weighted image demonstrating heterogenous mild enhancement within the right ventricular mass (white arrow).

stigmata of von Hippel-Lindau (VHL) disease such as renal tumours, but it was unremarkable. The patient's family history was also negative for any relevant illnesses.

A craniotomy with complete excision of the tumour was performed. A histopathologic examination again confirmed the diagnosis of HB. The postoperative course was uneventful.

Discussion

HBs are benign vascular tumours of uncertain origin (World Health Organization grade 1) that comprise 2% of all intracranial tumours and present equally in both sexes.³ They usually present sporadically, but approximately 20–30% of cases are linked to VHL, which is an autosomal dominant inherited disorder with incomplete expression and penetrance.³

Headache is the most common complaint followed by *ataxia*. Less frequent presentations include motor palsies, visual disturbances and seizures. Polcythaemia can be seen in 10–50% of patients with infratentorial HB but rarely in supratentorial HB.⁴

The most common locations of HB are infratentorial, particularly in the cerebellum (80–85%), but they have been described throughout the central nervous system (CNS). Supratentorial HBs are rare, accounting for 4% of sporadic cases and 13% of cases with VHL.^{4,5} Intraventricular HB and, in particular, the lateral ventricle form are very rare. Only a few cases have been reported in medical literature, some of them associated with VHL and others not [Table 1]. All reported intraventricular HBs have been solid and larger than those located elsewhere in the body, likely because of the space available to accommodate such masses before they produce symptoms.⁵

Lateral ventricular tumours include a wide variety of benign and malignant types. The most relevant differential diagnosis of a mass in the lateral ventricle in this particular age group includes subependymoma, which is commonly associated with hydrocephalus and often shows cystic components and calcifications but rarely haemorrhage; central neurocytoma that commonly demonstrates calcifications and cyst-like spaces but rarely is associated with ventricular or parenchymal haemorrhage, and metastasis, particularly from

Table 1: Summary of the reported cases of intraventricular hemangioblastoma*

Author	Age in years/sex	Site	Number	VHL
Rho <i>et al.</i> ⁹ 1969	58/M	Third ventricle + cerebellum + spinal cord	Multiple	Yes
Diehl <i>et al.</i> ¹ 1981	20/M	Lateral ventricle + cerebellum + medulla	Multiple	Yes
Loftus <i>et al.</i> ¹⁰ 1984	63/M	Third ventricle	Solitary	No
Murakami <i>et al.</i> ¹¹ 1985	31/M	Lateral ventricle + cerebellum	Multiple	Positive family history
Katayama <i>et al.</i> ¹² 1987	30/M	Third ventricle	Solitary	No
Fujii <i>et al.</i> ² 1987	70/F	Fourth ventricle	Solitary	No
Ho <i>et al.</i> ¹³ 1990	44/F	Lateral ventricle	Solitary	Positive family history
Isaka <i>et al.</i> ¹⁴ 1999	47/F	Third ventricle + cerebellum	Multiple	No
Prieto <i>et al.</i> ⁵ 2005	73/M	Lateral ventricle	Solitary	Yes
Son <i>et al.</i> ⁴ 2009	55/M	Fourth ventricle	Solitary	No
Jaggi <i>et al.</i> ¹⁵ 2009	30/M	Lateral ventricle	Solitary	No
Present case 2011	70/M	Lateral ventricle	Solitary	No

All reported cases were solid in nature
VHL = Von-Hippel-Lindau disease; M = male; F = female.

renal and lung cancers, which can be associated with haemorrhage. It usually shows intense enhancement.

The imaging appearance in our case did not fit any of these more common lesions. Our case is also different from the other reported intraventricular HB cases because it showed only mild heterogeneous enhancement instead of the reported intense homogenous enhancement.

HB most commonly presents as a cystic lesion with a mural nodule (60%) and less commonly as a solid lesion (20–29%), which tends to bleed more than cystic HB.^{3,6,7} Spontaneous macroscopic haemorrhage is uncommon among HBs despite their known vascular nature but, when it happens, it usually presents like a SAH or intracerebral

bleeding with less frequent occurrence in cerebral ventricles and the spinal cord. This has only been confirmed from spinal HBs, according to the review by Prieto *et al.*, with no cases among their intracranial counterparts.⁵ Interestingly, the current case showed extensive superficial siderosis indicating the presence of SAH which seemed to originate from the intraventricular haemorrhage by the circulating cerebrospinal fluid.

Parenchymatous haemorrhage was reported in the cerebrum, spinal cord and intratumoural. Intratumoural bleeding was very prominent in our case; this was previously reported in only one spinal HB which was also associated with SAH.⁸ Ventricular haemorrhage from HB appears to be uncommon. Only a few cases have been reported; these have referred to ventricular bleeding as the spread of a parenchymatous clot or as a reflux from the subarachnoid space. However, a pure ventricular haemorrhage from HB was reported by Fujii *et al.*² In this case, a CT scan showed the presence of blood within the third and fourth ventricles, but the tumour was unnoticed. Brainstem HB was diagnosed at autopsy. The average diameter of the HB nodules that bled was 2.57–3 cm, which is in accordance with our case. In fact, the risk of haemorrhage was found to increase with the increasing size of the HB.^{3,5}

To our knowledge, our case is the second one reported with a direct haemorrhage, but is the first case of a sporadic lateral ventricular HB combined with overt ventricular haemorrhage and SAH as well.

Conclusion

Tumours of the lateral ventricle include a large variety of benign and malignant lesions such as subependymoma, neurocytoma and metastatic cancers. Although intraventricular, HB is very rare and is increasingly being reported in the literature. Our case is unique because it was sporadic and caused direct ventricular haemorrhage as well as SAH. We recommend that HB should be included in the differential diagnosis of intraventricular tumours, especially when associated with haemorrhage and when the imaging appearances do not fit those of the more common intraventricular tumours.

References

1. Diehl PR, Symon L. Supratentorial intraventricular hemangioblastoma: Case report and review of literature. *Surg Neurol* 1981; 15:435–44.
2. Fujii H, Higashi S, Hashimoto M, Shouin K, Hiyase H, Kimura M, et al. Hemangioblastoma presenting with fourth ventricular bleeding: Case report. *Neurol Med Chir* 1987; 27:545–9.
3. Pedro JR, Rodriguez FA, Niguez BE, Sanchez JF, Lopez-Guerrero AL, Murcia MF. Massive hemorrhage in hemangioblastomas. Literature review. *Neurosurg Rev* 2010; 33:11–26.
4. Son RC, Byun WM, Lee HJ, Jang HW, Choi JH. Hemangioblastoma of the fourth ventricle. *J Korean Soc Radiol* 2009; 61:211–4.
5. Prieto R, Roda JM. Hemangioblastoma of the lateral ventricle: Case report and review of the literature. *Neurocirugía* 2005; 16:58–62.
6. Iyigün ÖL, Cokluk C, Aydin K, Yildiz L, Rakunt C, Celik F. Supratentorial leptomenigeal hemangioblastoma mimicking a meningioma without von Hippel-Lindau complex. *Turkish Neurosurg* 2004; 14:25–7.
7. Choyke PL, Glenn GM, Walther MM, Patronas NJ, Linehan WM, Zbar B. Von Hippel-Lindau disease: Genetics, clinical and imaging features. *Radiology* 1995; 146:629–42.
8. Kormos RL, Tucker WS, Bilbao JM, Gladstone RM, Bass AG. Subarachnoid hemorrhage due to a spinal cord hemangioblastoma: Case report. *Neurosurgery* 1980; 6:657–60.
9. Rho YM. Von Hippel-Lindau's disease: A report of five cases. *Can Med Assoc J* 1969; 101:135–42.
10. Loftus CM, Marquardt MD, Stein BM. Hemangioblastoma of the third ventricle. *Neurosurgery* 1984; 15:67–72.
11. Murakami H, Toya S, Otani M, Sato S, Ohiera T, Takenaka N, et al. A case of concomitant posterior fossa and supratentorial hemangioblastoma. *No Shinkei Geka* 1985; 13:175–9.
12. Katayama Y, Tsubokawa T, Miyagi A, Goto T, Miyagami M, and Suzuki K. Solitary hemangioblastoma within the third ventricle. *Surg Neurol* 1987; 27:157–62.
13. Ho YS, Plets C, Goffin J, Dom R. Hemangioblastoma of the lateral ventricle. *Surg Neurol* 1990; 33:407–12.
14. Isaka T, Horibe K, Nakatani S, Maruno M, Yoshimie T. Hemangioblastoma of the third ventricle. *Neurosurg Rev* 1999; 22:140–4.
15. Jaggi RS, Premsagar IC, Abhishek. Hemangioblastoma of the lateral ventricle. *Neurol India*; 2009:677–9.