

Successful Management of Pheochromocytoma using Preoperative Oral Labetalol and Intraoperative Magnesium Sulphate Report of four cases

*Sanath Kumar B. S.,¹ Rohit Date,¹ Nicholas Woodhouse,² Omayma El-Shafie,³ Karin Nollain¹

معالجة ناجحة لورم القواتم باستخدام دواء لابيتالول عن طريق الفم قبل العملية وإستخدام كبريتات المغنيسيوم بالتسريب أثناء العملية الجراحية تقرير أربعة حالات

ساناث كومار. روهيت ديت. نيكولاس ودهاوس. أميمه الشافعي. كارن نولين

ABSTRACT: Pheochromocytoma is a rare neuroendocrine catecholamine-secreting tumour. This type of tumour poses multidimensional anaesthetic challenges as it has an unpredictable clinical course during surgical resection. The alpha-blocking agent phenoxybenzamine remained the mainstay in preoperative preparation before the introduction of beta-blocking agents. We report four cases operated between 2009–2012 at Sultan Qaboos University Hospital, Muscat, Oman. The cases were prepared with oral labetalol, as the alpha-blocking drug phenoxybenzamine was not immediately available. Responses to simulated stress were tested in the theatre before surgery. Anaesthesia was induced under invasive arterial pressure monitoring and magnesium sulphate infusion. Rare intraoperative surges in blood pressure during tumour manipulation were treated with sodium nitroprusside infusions and phentolamine boluses. All of the patients had an uneventful postoperative recovery. Preoperative treatment with labetalol has rarely been reported and can be considered as a potential therapeutic option with optimal patient monitoring if phenoxybenzamine is unavailable.

Keywords: Pheochromocytoma; Labetalol; Phenoxybenzamine; Phentolamine; Magnesium Sulfate; Intraoperative Care; Case Report; Oman.

المخلص: ورم القواتم في الغدة الكظرية حالة نادرة تسبب ارتفاع هرمون الأدرنالين. هذا النوع من الورم يفرض تحديات متعددة عند عملية التخدير لأنه يؤدي إلى ارتفاع حاد في ضغط الدم ومضاعفات سريرية لا يمكن التنبؤ بها أثناء الاستئصال الجراحي. تبقى عقارات حاصرات الألفا: فينوكسي بنزامين العماد الأول في السيطرة على ارتفاع ضغط الدم والتخدير لما قبل الجراحة قبل ظهور عقارات حاصرات البيتا. في هذا التقرير نستعرض أربع حالات أجريت لهم عمليات جراحية بين 2009-2012 في مستشفى جامعة السلطان قابوس، مسقط، سلطنة عمان. تم التحضير لهذه الحالات بإعطاء لابيتالول عن طريق الفم لأن عقار فينوكسي بنزامين لم يكن متوفرا في الوقت المناسب. تم اختيار الاستجابة للإجهاد المستحث في غرفة العمليات قبل الجراحة. تم التخدير تحت مراقبة الضغط الشرياني داخل الشرايين مع تسريب كبريتات المغنيسيوم. ارتفاعات ضغط الدم نادرة أثناء عملية استئصال الورم وقد تم علاجها بتسريب مادة صوديوم نيتروبروسيد وعقار فنتول أمين. وقد تعافى جميع المرضى المذكورين بدون مضاعفات بعد العمليات التي أجريت لهم. نادرا ماتم الإبلاغ عن استخدام علاج لابيتالول قبل الجراحة ويمكن اعتباره خيارا علاجيا محتملا في ظل عدم توافر عقار فينوكسي بنزامين تحت المراقبة الطبية الأمثل للمريض.

مفتاح الكلمات: ورم القواتم؛ لابيتالول؛ فينوكسي بنزامين؛ فينتولامين؛ كبريتات المغنيسيوم؛ رعاية جراحة داخلية؛ تقارير حالات؛ عمان.

PHAECHROMOCYTOMA IS A NEURO-endocrine tumour (NET) which presents multidimensional challenges during surgical resection in spite of our improved understanding of its physiological and clinical behaviour. The most common manifestations of this clinical condition include hypertension, headaches, palpitations, diaphoresis (episodic sweating) and feelings of doom. The incidence of pheochromocytoma in the general population is 1–8/1,000,000.¹ The triad of headaches,

diaphoresis and palpitations is found in 20–40% of patients while 13% remain asymptomatic with high levels of catecholamines due to the downregulation of receptors.¹ Five types of genes are known to be important in hereditary pheochromocytomas and paragangliomas; these are found in 25% of patients with pheochromocytoma [Table 1]. Genes encoding succinate dehydrogenase subunits D (*SDHD*) and B (*SDHB*) are found to be implicated in familial non-syndromic pheochromocytomas.^{1,2}

Table 1: Genetic correlations in pheochromocytomas

Genetic basis of pheochromocytomas				
Familial	Bilateral	Malignant	Multiple	
<i>SDHD</i>	<i>RET</i>	<i>SDHB</i>	<i>SDHD</i>	
<i>SDHB</i>	<i>VHL</i>	<i>VHL</i>	<i>SDHB</i>	
<i>VHL</i>	<i>SDHD</i>	<i>VHL</i>		
<i>RET</i>				
Frequency of susceptibility genes in patients with pheochromocytoma or paraganglioma in percent				
<i>RET</i>	<i>VHL</i>	<i>NF1</i>	<i>SDH</i>	Others
5	9	2	<i>SDHD</i> : 5 <i>SDHC</i> : 1 <i>SDHB</i> : 5	<i>SDHAF2</i> : <1 <i>SDHA</i> : <1 <i>TMEM127</i> : 2 MAX: <1

RET = roto-oncogene; *VHL* = von Hippel-Lindau disease tumour suppressor gene; *NF1* = neurofibromatosis type 1 tumour suppressor gene; *SDH* = succinate dehydrogenase complex with subunit genes *SDHB*, *SDHC* and *SDHD*; *MAX* = MYC-associated factor X gene.

Different drugs and anaesthetic techniques are used for the perioperative management of patients with pheochromocytoma.³⁻⁵ Although α -adrenoceptor antagonists are the mainstay of perioperative blood pressure control, the use of various combinations of α - and β -adrenoceptor antagonists has been reported.³⁻⁵ Pretreatment with oral labetalol, as used in these cases, has rarely been reported, whereas intravenous labetalol and magnesium sulphate have been used for the rapid preparation of a patient with a pheochromocytoma.⁶ The following four cases highlight the possibility of using oral labetalol for preoperative management. The findings indicate that labetalol may be used in the preoperative management of pheochromocytoma as a therapeutic option, especially if phenoxybenzamine is not available.

Two of the four cases of pheochromocytoma were siblings. One of the siblings presented with severe episodic hypertension (Case 1) and the other with postural hypotension after standing for 30

Table 2: Plasma levels of circulating catecholamine and chromogranin in the four patients

Case	NADR in pmol/L	Adrenaline in pmol/L	Dopamine in pmol/L	CGA in μ g/L
1	23,670	140	266	700
2	32,048	<54	3,012	300
3	38,400	1,104	-	-
4	3,294	240	64	1,233
Normal ranges	650–2,433	<273	<475	27–94

NADR = noradrenaline; CGA = plasma catecholamine and chromogranin A.

minutes (Case 2). However, when the latter was subjected to simulated stressful conditions in the anaesthesia induction room, he developed severe tachycardia and hypertension. The other two patients had long-established histories of serious classical pheochromocytoma symptoms (Cases 3 and 4). None of the cases had comorbidities. All underwent open adrenalectomies and were operated on between 2009–2012 at Sultan Qaboos University Hospital, Muscat, Oman.

Case 1

A 13-year-old girl presented with a three-year history of headaches, sweating, palpitations and severe hypertension. On initial admission to a peripheral hospital, her blood pressure was 180/120 mmHg. The diagnosis of pheochromocytoma was made based on a computed tomography (CT) scan of the abdomen, which showed bilateral adrenal masses. Her plasma catecholamine and chromogranin A (CGA) levels were high [Table 2]. The initial echocardiogram (ECHO) showed a systolic dysfunction with global hypokinesia and an ejection fraction (EF) of 46%. Since phenoxybenzamine is not available in Oman, she was treated with oral labetalol up to 400 mg twice a day (BD). After six weeks, the blood pressure was under control, the ECHO was normal and the EF was 64%. The haematocrit was 31 g/dL, indicating an expansion of the extracellular volume. Before being scheduled for a bilateral adrenalectomy, she was taken to the induction room to undergo a simulated stress test while her blood pressure and heart rate were monitored. Her haemodynamics remained within normal limits at this time as well as during subsequent postural changes.

The night before the surgery, the patient received lorazepam, a fluid preloaded with Ringer's lactate solution, and midazolam as premedication. Before inducing anaesthesia, a bolus of magnesium sulphate (50 mg/Kg) was given followed by a maintenance dose of 15 mg/Kg/hour. Under invasive arterial pressure monitoring, the induction was done with fentanyl, propofol, cisatracurium and lidocaine (1.5 mg/Kg) prior to intubation. During the manipulation of the tumour, hypertensive derangements with short spikes up to 200 mmHg systolic were controlled with an infusion of sodium nitroprusside (SNP) and boluses of phentolamine, a potent α -adrenoceptor antagonist. Under an adequate volume replacement and hydrocortisone supplementation, the patient remained haemodynamically stable after tumour

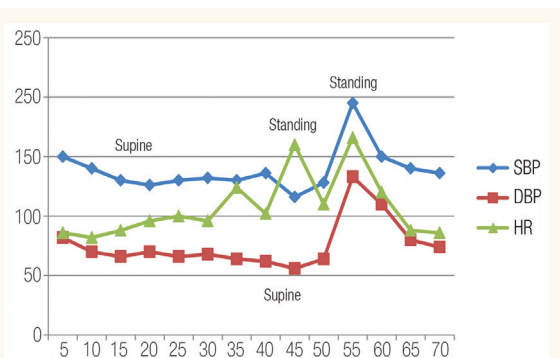


Figure 1: Marked postural fluctuations in heart rate, systolic blood pressure and diastolic blood pressure in Case 2 before starting treatment with labetalol.

SBP = systolic blood pressure; DBP = diastolic blood pressure; HR = heart rate.

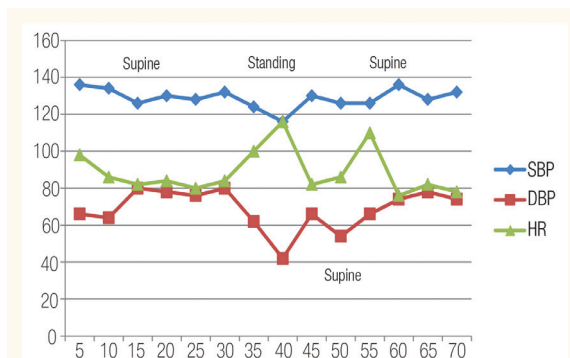


Figure 2: After two weeks on labetalol, the haemodynamic variables of Case 2 showed minimal postural fluctuations.

SBP = systolic blood pressure; DBP = diastolic blood pressure; HR = heart rate.

removal without any vasoactive drugs.

Case 2

A 16-year-old boy, the brother of the first case, was diagnosed with pheochromocytoma by CT scan after elevated CGA levels were found during family screening. He had a single right adrenal tumour but was asymptomatic apart from attacks of fainting during long periods of standing. His blood pressure and heart rate were normal despite high plasma noradrenaline levels [Table 1]. The routine investigations, including electrocardiography (ECG) and ECHO, were normal. The patient's response to simulated stressful conditions was cross-checked in the anaesthesia induction room; he developed severe tachycardia with 170 beats per minute and his blood pressure rose to 190/130 mmHg; this was associated with dizziness when in an upright position [Figure 1]. As a result, the patient was treated preoperatively with labetalol (100 mg BD) for two weeks. After that time, he was exposed to simulated stress again without developing tachycardia or hypertension [Figure 2]. The preoperative preparations and induction of anaesthesia were performed similarly to the first case. During the manipulation of the tumour, the blood pressure spikes were controlled with infusions of SNP and boluses of phentolamine. After the removal of the tumour, the patient required a low dose of phenylephrine infusion for a short period.

Case 3

A 37-year-old woman presented with a three-year history of severe paroxysmal headaches, palpitations and hypertension. A CT scan of the abdomen showed a right adrenal tumour with elevated plasma

catecholamine and CGA levels [Table 2]. The patient had been on labetalol (400 mg BD) during the previous month and her symptoms had mostly subsided with only short episodes of palpitations. The ECG and ECHO were normal. During the stress simulation, the haemodynamics parameters remained within normal limits with minimal postural changes and so the patient was admitted for an open right adrenalectomy. The preoperative preparations of hydration, anaesthesia induction and intraoperative management were similar to those of the previous two cases. The patient had more frequent hypertensive derangements during the tumour dissection, which were controlled by phentolamine boluses. She did not require any vasopressor support after the removal of the tumour.

Case 4

A 50-year-old woman presented with a more than three-year history of headaches, palpitations and sweating, and had a palpable painful mass in her upper left abdomen. The CT scan revealed an extensive infarction of a huge left adrenal tumour and only slightly increased plasma levels of noradrenaline [Table 2]. Although she was normotensive, a small dose of labetalol (25 mg BD) was given for 15 days prior to surgery and her symptoms subsided to only short episodes of palpitations. The ECG and ECHO were normal. During the stress simulation, her haemodynamics remained within normal limits with no postural changes. The patient was admitted for an open left adrenalectomy. The preoperative preparations and anaesthetic management were similar to those of the previous three cases. However, her blood pressure did not fluctuate much during the tumour dissection except for a mild hypertensive episode (170/90 mmHg) which was managed with a

phentolamine bolus. She did not require vasopressor support after the removal of the tumour.

All four cases had uneventful postoperative periods and were extubated in the Intensive Care Unit after a few hours of observation.

Discussion

The problems surrounding the pre- and perioperative management of pheochromocytoma have been well described in the literature.^{3,4} The main objective in the preoperative management of these patients is to control the blood pressure, heart rate and arrhythmias, and to allow restoration of blood volume.^{3,5}

There is no consensus on the best pharmacological agent or optimal duration of therapy for the preparation of these patients for surgery. Traditionally, phenoxybenzamine, a non-selective α -adrenergic antagonist, has been the mainstay of perioperative treatment.^{4,6–9} The greatest advantage of using phenoxybenzamine is its long duration of action. This is due to its non-competitive irreversible blockade which helps to avert the effects of surges of catecholamine release, particularly during the surgical manipulation of the tumour.^{4,10,11} After the removal of the tumour, the side-effects, such as postural hypotension and somnolence, may continue into the postoperative period; additionally, patients may require vasopressor support.^{4,12} However, phenoxybenzamine blocks α -2-adrenoreceptors, which may facilitate the noradrenaline release, resulting in undesirable chronotropic and inotropic effects.¹² In some cases, these have been controlled with adjuvant β -adrenoreceptor antagonists.^{4,13} The other disadvantages of using phenoxybenzamine are its other side-effects—headaches and stuffy nose—which have been reported to reduce patient compliance with the medication regime.^{3,4}

A variety of pharmacological agents, like prazosin, doxazosin and calcium channel blockers, have also been used in the preparation of patients with pheochromocytoma.^{3,4,6} In the current case series, since phenoxybenzamine was not available, labetalol was used which is known to combine a selective competitive α -1- and non-selective competitive β -adrenoreceptor antagonist with the ratio of α : β antagonism being 1:3 after oral and 1:7 after intravenous administration.¹⁴ Cases have been reported where intravenous labetalol along with magnesium sulphate was used for the rapid preparation of patients with pheochromocytoma without untoward effects.⁷ However, there is also a report in

the literature of one incident of cardiovascular collapse where intravenous labetalol was used in an emergency to control blood pressure in a patient with an undiagnosed pheochromocytoma.¹⁵ Two additional reports of oral labetalol used for preoperative preparation have been recorded. One case displayed a hypertensive response while in the other report three patients were successfully prepared without untoward incidents.^{16–18}

The administration of labetalol lowers systemic blood pressure by decreasing systemic vascular resistance due to the α -1-blockade where reflex tachycardia is attenuated by a simultaneous β -blockade.⁷ Continued oral labetalol medication on the day of surgery has one advantage—the peak action of the drug occurs four hours after administration, acts during the operation on the active site and then wears off at the right time. This contributes to the patient's circulatory stability after the removal of the tumour.

Two of the four patients in the current series, who responded normally to the simulated stress and were classically hypertensive, responded well to 100–400 mg of labetalol BD. One of the normotensive patients, Case 2, had high noradrenaline levels. When exposed to simulated stress, he responded adversely with marked tachycardia and hypertension. However, two weeks after starting labetalol, a repeated stress test showed great improvement in the patient. Given the history of this case, the authors support the recommendation to prepare normotensive pheochromocytomas with an α -adrenergic blockade.^{3,19,20} Case 4, who had an enormous infarcted adrenal mass with only slightly elevated noradrenaline levels, responded normally to a stress test after a small dose (25 mg) of labetalol BD.

Pacak explains the wide range of clinical presentations among patients with pheochromocytoma as a “desensitisation” of the receptors. Therefore, some patients will need significant amounts of adrenoreceptor blockers while others may not—despite high-circulating catecholamine concentrations.¹⁶ From the first use of magnesium sulphate in the anaesthetic management of pheochromocytoma, there have been multiple case series which have confirmed its use during surgery. It has also been used in three patients with pheochromocytoma, all of whom presented with severe cardiovascular instability.^{21–23}

In the current cases series, magnesium sulphate was used in all cases as it inhibits the release of catecholamine from the adrenal medulla and adrenergic nerve endings; it has direct vasodilatory effects and anti-arrhythmic properties.²¹ Since the patients in this series were on oral labetalol and the

severity of blood pressure derangements during surgery could not be anticipated, the potent alpha-blocker, phentolamine, was kept available and used during the tumour dissection. In addition, magnesium sulphate infusions were used in all of the patients—from the induction of anaesthesia until the final removal of the tumour. This may have contributed to the patients' successful outcomes. In the postoperative period, especially after the removal of the tumour, there were no significant hypotensive episodes which required inotropic support. All patients were haemodynamically stable and extubated after a few hours of observation.

Conclusion

The traditional view of a preoperative stabilisation phase with phenoxybenzamine has stood the test of time. Although the use of labetalol is controversial as the first choice of treatment in the preparation of these types of patients, this pilot report of four cases has shown that oral labetalol, in combination with magnesium sulfate used intraoperatively, may be a potential therapeutic option in patients with pheochromocytoma if phenoxybenzamine is not available. Despite the fact that these patients were exposed to simulated stress, the authors do not recommend this as a routine practice; the Roizen criteria should still be met if applicable. This case series encourages further study of the use of labetalol in order to collect and publish the necessary data and so establish a safe recommendation.

References

1. Subramaniam R. Pheochromocytoma: Current concepts in diagnosis and management. *Curr Anaesth Crit Care* 2011; 1:104–10. doi: 10.1016/j.tacc.2011.01.009.
2. Galan SR, Kann PH. Genetics and molecular pathogenesis of pheochromocytoma and paraganglioma. *Clin Endocrinol (Oxf)* 2013; 78:165–75. doi: 10.1111/cen.12071.
3. Prys-Roberts C. Pheochromocytoma: Recent progress in its management. *Br J Anaesth* 2000; 85:44–57. doi: 10.1093/bja/85.1.44.
4. Hull CJ. Pheochromocytoma: Diagnosis, preoperative preparation and anaesthetic management. *Br J Anaesth* 1986; 58: 1453–68. doi: 10.1093/bja/58.12.1453.
5. Bajwa S, Bajwa SK. Implications and considerations during pheochromocytoma resection: A challenge to the anesthesiologist. *Indian J Endocrinol Metab* 2011; S337–44. doi: 10.4103/2230-8210.86977.
6. Russell WJ, Metcalfe IR, Tonkin AL, Frewin DB. The preoperative management of pheochromocytoma. *Anaesth Intensive Care* 1998; 26:196–200.
7. Poopalalingam R, Chin EY. Rapid preparation of a patient with pheochromocytoma with labetalol and magnesium sulfate. *Can J Anaesth* 2001; 48:876–80. doi: 10.1007/BF03017353.
8. Stenstrom G, Haljamae H, Tisell LE. Influence of pre-operative treatment with phenoxybenzamine on the incidence of adverse cardiovascular reactions during anesthesia and surgery for pheochromocytoma. *Acta Anaesthesiol Scand* 1985; 29:797–803. doi: 10.1111/j.1399-6576.1985.tb02303.x.
9. Geoghegan JG, Emberton M, Bloom SR, Lynn JA. Changing trends in the management of pheochromocytoma. *Br J Surg* 1998; 85:117–20. doi: 10.1046/j.1365-2168.1998.02875.x.
10. Hoffman BB, Lefkowitz RJ. Catecholamines, sympathomimetic drugs and adrenergic receptor antagonists. In: Hardman JG, Limbird LE, Molinoff PB, Ruddon RW, Gilman AG. Eds. *Goodman & Gilman's The Pharmacological Basis of Therapeutics*. 9th ed. New York, USA: McGraw-Hill, 1996. Pp. 199–248.
11. Brown BR Jr. Anaesthesia for pheochromocytoma. In: Roberts CP, Brown BR Jr, Nunn JF, Eds. *International Practice of Anaesthesia*. 6th ed. Oxford, UK: Butterworth-Heinemann, 1996. Pp. 1/83/1–7.
12. Langer SZ. Presynaptic regulation of the release of catecholamines. *Pharmacol Rev* 1980; 32:337–62.
13. Manger WM, Gifford JW Jr. Pheochromocytoma: A clinical overview. In: Swales JD. Ed. *Textbook of Hypertension*. Oxford, UK: Wiley-Blackwell, 1994. Pp. 941–58.
14. MacCarthy EP, Bloomfield SS. Labetalol: A review of its pharmacology, pharmacokinetics, clinical uses and adverse effects. *Pharmacotherapy* 1983; 3:193–219. doi: 10.1002/j.1875-9114.1983.tb03252.x.
15. Kuok CH, Yen CR, Huang CS, Ko YP, Tsai PS. Cardiovascular collapse after labetalol for hypertensive crisis in an undiagnosed pheochromocytoma during cesarean section. *Acta Anaesthesiol Taiwan* 2011; 49:69–71. doi: 10.2165/00128415-201113660-00075.
16. Pacak K. Preoperative management of the pheochromocytoma patient. *J Clin Endocrinol Metab* 2007; 92:4069–72. doi: 10.1210/jc.2007-1720.
17. Reach G, Thibonnier M, Chevillard C, Corvol P, Milliez P. Effect of labetalol on blood pressure and plasma catecholamine concentrations in patients with pheochromocytoma. *Br Med J* 1980; 280:1300–1. doi: 10.1136/bmj.280.6227.
18. Briggs RS, Birtwell AJ, Pohl JE. Hypertensive response to labetalol in pheochromocytoma. *Lancet* 1978; 311:1045–6. doi: 10.1016/S0140-6736(78)90772-9.
19. Agarwal A, Gupta S, Mishra AK, Singh N, Mishra SK. Normotensive pheochromocytoma: Institutional experience. *World J Surg* 2005; 29:1185–8. doi: 10.1007/s00268-005-7839-4.
20. Gonzalez-Pantaleon AD, Simon B. Nonclassic presentation of pheochromocytoma: Difficulties in diagnosis and management of the normotensive patient. *Endocr Pract* 2008; 14:470–3. doi: 10.4158/EP.14.4.470.
21. James MF. Use of magnesium sulphate in the anaesthetic management of pheochromocytoma: A review of 17 anaesthetics. *Br J Anaesth* 1989; 62:616–23. doi: 10.1093/bja/62.6.616.
22. James MF. Use of magnesium sulphate in the anaesthetic management of pheochromocytoma. *Anesthesiology* 1985; 62:188–90.
23. James MF, Cronjé L. Pheochromocytoma crisis: The use of magnesium sulphate. *Anesth Analg* 2004; 99:680–6. doi: 10.1213/01.ANE.0000133136.01381.52.