

Vascular Anomalies in Children Misdiagnosed with Asthma Case series

Hashim Javad,¹ Khalfan Al-Sineidi,¹ Anas A. Abdelmogheth,¹ Dilip Sankhla,² Humoud Al-Dhuhli,² Sinan I. Azzawi,²
*Mohamed A. El-Naggari¹

عيوب الأوعية الدموية لدى الأطفال ذوى التشخيص الخطأ كحالات الربو سلسلة من الحالات

هاشم جافاد، خلفان السنيدي، انس الوجود عبد المغيث، ديليب سانكلا، حمود الذهلي، سنان عزوي، محمد النجاري

ABSTRACT: In most asthmatic children, inhaled steroids can relieve and control the symptoms of asthma. Persistent wheezing and respiratory symptoms in young children despite appropriate treatment may indicate other diagnostic considerations. Delays in this diagnosis can result in unnecessary investigations, inappropriate treatment and further complications. We report three patients who presented to Sultan Qaboos University Hospital, Muscat, Oman, in the period between September 2010 and May 2012 with persistent wheezing due to compression of the trachea caused by vascular anomalies. All patients had double aortic arches putting pressure on the trachea, leading to respiratory manifestations and feeding problems. Following surgery, all cases showed improvement and no longer required medication. Without clinical suspicion and appropriate imaging, congenital vascular anomalies may remain undetected for years. Infants and children with chronic wheezing should be evaluated for vascular anomalies as soon as possible. General practitioners should refer all such patients to a tertiary-level hospital for further investigations and management.

Keywords: Vascular Malformations; Aortic Arch Syndromes; Asthma; X-Ray Computed Tomography; Wheezing; Stridor; Case Report; Oman.

المخلص: في معظم الأطفال المصابين بالربو يمكن للستيرويدات المستنشقة أن تخفف وتتحكم في أعراض الربو. قد يشير استمرار الصفير وأعراض الجهاز التنفسي عند الأطفال الصغار رغم العلاج المناسب إلى اعتبارات تشخيصية أخرى. يمكن أن يؤدي التأخير في التشخيص إلى إجراء فحوصات لا داعي لها، وتلقي علاج غير مناسب و مزيد من التعقيدات. نعرض هنا في هذا التقرير ثلاثة مرضى قدموا إلى مستشفى جامعة السلطان قابوس، مسقط، سلطنة عمان، في الفترة ما بين سبتمبر 2010 حتى مايو 2012 وهم يعانون من صفير مستمر بسبب الضغط على القصبة الهوائية الناجم عن عيوب في الأوعية الدموية. شكل ازدواج القوس الأبهرى ضغطاً على القصبة الهوائية في جميع المرضى، مما أدى إلى ظهور أعراض الجهاز التنفسي ومشاكل في التغذية. أظهرت جميع الحالات تحسناً بعد إجراء الجراحة، وعدم الحاجة إلى الأدوية. بدون الاشتباه السريري والتصوير الطبي المناسب قد يتأخر اكتشاف عيوب الأوعية الدموية إلى سنوات. ينبغي تقييم الرضع والأطفال الذين يعانون من الصفير المزمن لاستبعاد عيوب الأوعية الدموية في أقرب وقت ممكن. يجب على الأطباء الممارسين تحويل جميع هؤلاء المرضى إلى مستشفى مركزي لإجراء مزيد من الفحوصات والعلاج.

مفتاح الكلمات: تشوهات الأوعية الدموية؛ متلازمة القوس الأبهرى؛ الربو؛ التصوير المقطعي لأشعة إكس؛ الصفير؛ صرير؛ تقرير حالة؛ عمان.

WHEEZING IS A COMMON MEDICAL problem during early childhood.^{1,2} Most of the conditions that cause wheezing in children are benign and self-limiting. However, when wheezing presents itself before the age of one year, it requires careful evaluation. Similarly, as noted by Payne *et al.*, a thorough reassessment of an asthmatic patient who is not responding to classic treatment is essential so as to establish the aetiology of the condition.³ Poorly controlled childhood asthma may be due to the improper use of inhalation devices, poor compliance to treatment or recurrent triggering factors.⁴ In a young child with a persistent wheeze who

is not responding to treatment, other rare causes need to be identified.

Aortic arch malformations occur in 3% of the general population.⁴ Usually, incomplete vascular anomalies of the aortic arch do not cause respiratory symptoms and, therefore, can remain undetected in childhood.⁵ However, significant respiratory and gastrointestinal symptoms are common with complete vascular anomalies due to the resulting compression of the trachea and oesophagus.⁶ A chest X-ray may show unremarkable findings or a right-sided aortic arch, with the absence of a left-sided aortic knuckle. A high index of suspicion alongside investigations such as

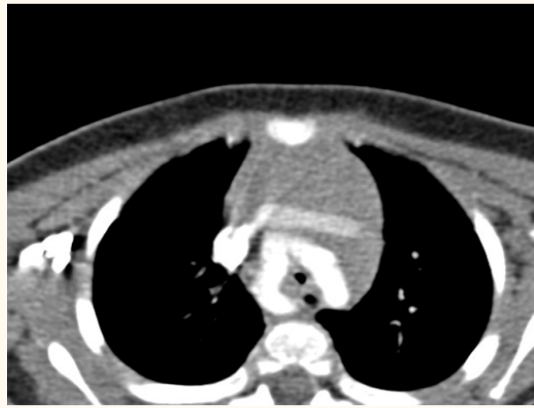

Figure 1: Axial computed tomography angiography image of the first case, demonstrating both aortic arches with a mildly compressed trachea and oesophagus.

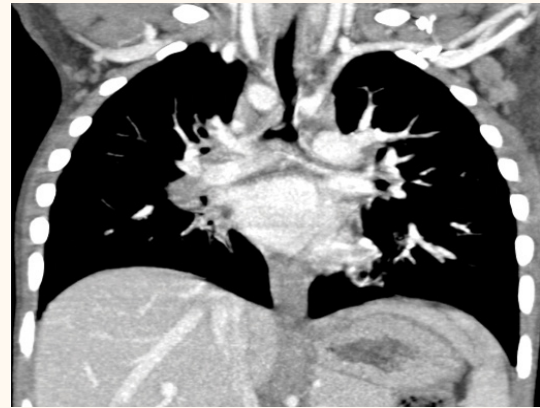


Figure 2: Coronal computed tomography angiography image of the second case, showing both aortic arches compressing the distal trachea.

upper gastrointestinal contrast studies, echocardiograms and computed tomography (CT) angiograms of the chest are critical in the diagnosis.⁷ The timely identification and treatment of a vascular anomaly is essential in order to prevent complications.

Case One

An eight-month-old male infant was referred to Sultan Qaboos University Hospital (SQUH) in Muscat, Oman, in October 2011 with persistent wheezing that had continued since birth. He was born by emergency Caesarian section due to fetal bradycardia; however, after birth, he demonstrated an acceptable Apgar score. From two weeks of age the infant had attended various health facilities as he had noisy breathing and mild difficulty with feeding. He showed no response to treatment with bronchodilators and steroids. On examination, it was found that the infant's growth parameters were below the third percentile. Biphasic wheezing was heard all over his chest by auscultation. Findings from other systemic examinations, as well as his vital signs and oxygen saturation levels, were normal.

A flexible endoscopy of the upper airway and chest X-rays showed no abnormal signs. However, the infant's symptoms worsened with time. An echocardiogram revealed a double aortic arch (DAA). A chest CT angiography confirmed this finding and showed that the DAA was pressing gently on the trachea and oesophagus [Figure 1]. The infant was operated on at 10 months of age. During surgery, pressure on the trachea and oesophagus from the DAA was observed and the posterior aortic arch was divided to release the obstruction. The infant's symptoms and growth parameters improved after surgery and he was not on any medication at the time of follow-up.

Case Two

A three-year-old male child was referred to SQUH in September 2010 with a history of wheezing, dysphagia and cyanosis while feeding. From the age of six months, he had been undergoing regular follow-up with an ear, nose and throat (ENT) surgeon at SQUH for suspected laryngomalacia. His growth parameters were between the 25th and 50th percentile. His vital signs and oxygen saturation levels were normal. On auscultation, wheezing was heard bilaterally.

A clinical examination of his cardiovascular system was unremarkable. Routine blood investigations and a chest X-ray showed no abnormal findings. A barium swallow test with fluoroscopy revealed an indentation of the oesophagus at the T4–T5 vertebral level. An echocardiogram revealed a left-sided hypoplastic aortic arch with two branches; the left carotid and left subclavian. The right aortic arch was dominant with both the right carotid and the subclavian arising from it. These findings were consistent with a diagnosis of DAA. A coronal CT angiogram showed both aortic arches compressing the distal trachea as well as the junction of both posterior arches [Figure 2].

At the age of three-and-a-half years, the patient underwent an operation whereby the posterior aortic arch was divided to release the obstruction. On follow-up, he was not taking any medication and was asymptomatic and thriving.

Case Three

A three-month-old female infant was referred to SQUH in May 2012 with noisy breathing, wheezing and difficulty with feeding since birth. She was born normally with a good Apgar score and a birth weight of 2.7 kg. Soon after the infant's birth, her parents

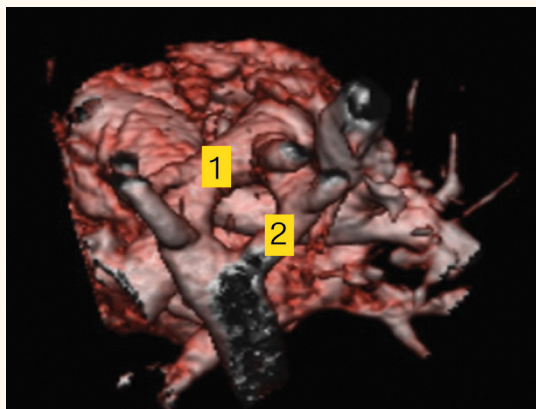


Figure 3: Three-dimensional volume-rendered computed tomography chest angiography image of the third case, showing a double aortic arch (marked 1 and 2).

noticed the aforementioned symptoms. It was also observed that she was not gaining any weight. She received nebulised bronchodilators and antibiotics which had no effect. Laryngomalacia was suspected by the SQUH ENT surgeon. The infant's growth parameters were below the third percentile and she had biphasic wheezing.

The findings of a chest X-ray were normal. A barium swallow test revealed a posterior indentation on the upper oesophagus which was suggestive of an extrinsic vascular compression. A CT chest angiogram was performed and showed a DAA compressing the trachea. A three-dimensional volume-rendered CT angiography of the chest also showed the DAA [Figure 3].

The infant was operated on at the age of 10 months. During the surgery, it was observed that the DAA was putting pressure on the trachea and oesophagus. The posterior aortic arch was therefore divided to release the obstruction. The infant's symptoms persisted for some time after surgery due to the indentation caused by the DAA on the trachea and oesophagus. However, on follow-up, a gradual improvement in her symptoms and growth parameters was seen and she was not on any medication.

A summary of the details and clinical findings for all three cases in this series is presented in Table 1.

Discussion

A DAA is a prevalent vascular ring malformation whereby the two arches surround the trachea and oesophagus.⁷ The paired aortic arch arteries fail to remodel properly, resulting in two aortic arches connecting both the ascending and descending aortas. The ascending aorta bifurcates anteriorly to the trachea and oesophagus, with one arch coursing to

Table 1: Summary of the details and clinical findings for the three presented patients with vascular anomalies

Detail/finding	Case		
	1	2	3
Age at presentation	Eight months	Three years	Three months
Gender	Male	Male	Female
Age at onset of symptoms	Since birth	Six months	Since birth
Presenting features	Persistent wheezing	Wheezing and dysphagia	Noisy breathing
Growth	FTT*	Normal [†]	FTT*
Development	AFA	AFA	AFA
Auscultation	Biphasic wheezing	Bilateral wheezing	Bilateral wheezing
CVS	UR	UR	UR
Chest X-ray	UR	UR	UR
Upper GI contrast study	Not performed	Indentation of upper oesophagus	Indentation of upper oesophagus
Echocardiogram	DAA	DAA	DAA
Chest CT angiogram	DAA	DAA	DAA
Diagnosis	DAA	DAA	DAA
Treatment received	Surgical division of PAA	Surgical division of PAA	Surgical division of PAA
Outcome	Cured	Cured	Slowly improving

FTT = failure to thrive; AFA = appropriate for age; CVS = chorionic villus sampling; UR = unremarkable; GI = gastrointestinal; DAA = double aortic arch; CT = computed tomography; PAA = posterior aortic arch.

*Below the third percentile. [†]Between the 25th and 50th percentile.

the left of the trachea and oesophagus and the other to the right.⁷ The arches rejoin into a single descending aorta behind the trachea and oesophagus, thereby completely encircling the two structures.⁷

In children with a DAA, stridor is considered a common clinical presentation, followed by recurrent respiratory infections, respiratory distress, wheezing and coughing.⁸ Gastrointestinal symptoms are usually elicited during the patient history and include dysphagia, feeding difficulty and vomiting.⁸ All three patients in this case series presented with breathing difficulties, wheezing and dysphagia. A dominant right-sided aortic arch raises clinical suspicion for a vascular ring. At present, CT and magnetic resonance imaging angiograms are used as an effective diagnostic and assessment tool for aortic arch anomalies, including DAA.⁹ A DAA compressing the trachea

and oesophagus in the first two cases of this series were confirmed by a CT angiogram. In these patients, compression of the trachea and oesophagus from the DAA was observed during surgery and the posterior aortic arch was divided to release the obstruction. Following surgery, both of the patients became asymptomatic.

A study by Stewart *et al.* revealed cleavage of the vascular ring in three out of 15 patients with a vascular ring.¹⁰ In the management of children with vascular rings, Phelan *et al.* indicated that a high index of clinical suspicion is required in order to ensure a rapid and timely diagnosis.¹¹ Mild vascular rings can be missed in very young patients and manifest only at an older age. However, noisy breathing sounds are usually the classical presentation soon after delivery.¹¹ These symptoms often worsen during a respiratory infection. Wheezing in a very young infant is another typical clinical presentation. Sometimes, the vascular ring can be misdiagnosed as cardiac disease, unless the history points to airway problems, as clinical examinations can appear normal.¹⁰ Multi-view chest imaging scans are very helpful in distinguishing many subtle pulmonary and cardiac abnormalities. Identification of the right-sided aortic arch on a chest radiograph is crucial as it may be associated with a ring anomaly.

Missed or late identification of vascular anomalies can result in unnecessary investigations and treatment, while a prolonged and inappropriate use of inhaled corticosteroids may cause hazardous effects on growth, bones and adrenal glands.¹² If the airway is compressed by a vascular ring for an extended period of time, it may cause a permanent indentation of the airway. Establishing the correct diagnosis and ensuring appropriate surgery will assist in the improvement of symptoms and the avoidance of unnecessary treatment. When treating a patient with poorly controlled persistent respiratory complaints, physicians should consider alternative diagnoses by carefully reviewing the patient history and chest images. Furthermore, all children with persistent wheezing should be referred to tertiary level hospitals for further investigations and management.

Conclusion

A diagnosis of bronchial asthma in young children should be made cautiously, after excluding other conditions that can cause persistent wheezing. Chronic or recurrent wheezing in young children who do not respond to classic treatment requires thorough reassessment to establish the aetiology and to avoid complications and unnecessary medication. In the absence of clinical suspicion and appropriate imaging,

congenital vascular anomalies can remain undetected until adulthood. General practitioners should refer all children with persistent wheezing for further investigations at a tertiary level hospital.

References

1. Taussig LM, Wright AL, Holberg CJ, Halonen M, Morgan WJ, Martinez FD. Tucson Children's Respiratory Study: 1980 to present. *J Allergy Clin Immunol* 2003; 111:661–75. doi: 10.1067/mai.2003.162.
2. Bloomberg GR. Recurrent wheezing illness in preschool-aged children: Assessment and management in primary care practice. *Postgrad Med* 2009; 121:48–55. doi: 10.3810/pgm.2009.09.2052.
3. Payne DN, Lincoln C, Bush A. Lesson of the week: Right sided aortic arch in children with persistent respiratory symptoms. *BMJ* 2000; 321:687–8. doi: 10.1136/bmj.321.7262.687.
4. Balfour-Lynn I. Difficult asthma: Beyond the guidelines. *Arch Dis Child* 1999; 80:201–6. doi: 10.1136/adc.80.2.201.
5. Humphrey C, Duncan K, Fletcher S. Decade of experience with vascular rings at a single institution. *Pediatrics* 2006; 117:e903–8. doi: 10.1542/peds.2005-1674.
6. Woods RK, Sharp RJ, Holcomb GW 3rd, Snyder CL, Lofland GK, Ashcraft KW, et al. Vascular anomalies and tracheoesophageal compression: A single institution's 25-year experience. *Ann Thorac Surg* 2001; 72:434–8. doi: 10.1016/S0003-4975(01)02806-5.
7. Juraszek AL, Fulton DR. Vascular Rings. From: www.uptodate.com/contents/vascular-rings Accessed: Jan 2014.
8. Backer CL, Mavroudis C, Rigsby CK, Holinger LD. Trends in vascular ring surgery. *J Thorac Cardiovasc Surg* 2005; 129:1339–47. doi: 10.1016/j.jtcvs.2004.10.044.
9. Felson B, Palayew MJ. The two types of right aortic arch. *Radiology* 1963; 81:745–59. doi: 10.1148/81.5.745.
10. Stewart JR, Kincaid OW, Titus JL. Right aortic arch: Plain film diagnosis and significance. *Am J Roentgenol Radium Ther Nucl Med* 1966; 97:377–89. doi: 10.2214/ajr.97.2.377.
11. Phelan E, Ryan S, Rowley H. Vascular rings and slings: Interesting vascular anomalies. *J Laryngol Otol* 2011; 125:1158–63. doi: 10.1017/S0022215111001605.
12. Pedersen S, O'Byrne P. A comparison of the efficacy and safety of inhaled corticosteroids in asthma. *Allergy* 1997; 52:1–34. doi: 10.1111/j.1398-9995.1997.tb05047.x.