

SUBMITTED 3 SEP 20

REVISION REQ. 12 NOV 20; REVISION RECD. 7 DEC 20

ACCEPTED 24 JAN 21

ONLINE-FIRST: APRIL 2021

DOI: <https://doi.org/10.18295/squmj.4.2021.048>

Askin's Tumour

Massive tumour with minimal symptoms

***Aqeel Hussain,¹ Alkesh K. Khurana,¹ Abhishek Goyal,¹ Deepti Joshi²**

Departments of ¹Pulmonary Medicine and ²Pathology, All India Institute of Medical Sciences, Bhopal, India

**Corresponding Author's e-mail: aqeelturabi09@gmail.com*

Introduction

A 33year old female presented to All India Institute of Medical Sciences, Bhopal, Madhya Pradesh, India in December 2019 with complaints of left sided chest discomfort for 4 months and progressively increasing shortness of breath for 1 month. She developed hoarseness of voice, chest pain and dysphagia 1 week before presenting to this hospital. Chest X-ray revealed a large homogenous opacity in left hemi thorax with tracheal and cardiac deviation to right side. (Figure 1a). Contrast enhanced computed tomography (CECT) of thorax revealed a single large heterogeneously enhancing soft tissue mass lesion occupying whole of left hemi thorax which measured 27cm×14.6cm×15.5 cm (Figure 1b). The lesion caused significant mass effect in form of gross contralateral mediastinal shift, inferior displacement of diaphragm, anterior displacement of spleen, encasement and obliteration of the left pulmonary artery and abutment and displacement of the left subclavian artery, arch of aorta, descending aorta without any luminal narrowing. No obvious bony lytic or sclerotic lesion was noted.

Ultrasonography (USG) guided fine needle aspiration cytology (FNAC) of the lesion was done which revealed malignant round cell tumor possibly primitive Neuroectodermal tumour (PNET). Biopsy of the lesion revealed malignant round cell tumour (Figure 2a). Immunohistochemistry of

the lesion was positive for CD 99 (Figure 2b). Lymphoid markers, WT-1 and EMA were negative confirming the diagnosis. Beyond CD99 positivity, characteristic site and morphology of the tumor supported the diagnosis of PNET. No blasts were observed on peripheral blood and bone marrow examination, excluding possibility of lymphoblastic malignancy. No desmoplasia was seen in the tumor stroma thereby excluding the diagnosis of desmoplastic small round cell tumor. Patient was started on chemotherapy with VAC-IE regimen after discussion in the multi-disciplinary team. Serum Lactate dehydrogenase (LDH) levels were 904 Units per liter (U/L). Bone marrow aspiration and biopsy done for staging purpose revealed hyper cellular marrow with erythroid hyperplasia and mild megaloblastosis with no evidence of marrow infiltration by tumour cells. Her performance status as per Eastern cooperative Oncology group scale was 3/5. Patient received first cycle of chemotherapy as per protocol and supportive treatment in form of feeding by nasogastric tube, analgesics and hydration. On 4th post chemo day patient developed hypoxemic respiratory failure which was managed with supplemental oxygen and antibiotics but respiratory failure worsened over the next few days and the patient succumbed to it.

Patient consent was obtained from the patients' husband to use the case record and images for publication purposes.

Comments

PNET of the thoracopulmonary region also referred to as Askin's tumour was first described in 1979 by Askin et al. and is a very rare entity.¹ It develops from the soft tissues of the chest wall, particularly in the paravertebral region. Clinical symptoms include painful chest wall mass and other associated symptoms like dyspnea, cough, weight loss and regional lymphadenopathy. A chest wall soft-tissue density mass, sometimes associated with rib erosion and/or pleural effusion, is the commonest radiographic manifestation. Sometimes it may only produce a vague discomfort and thereby delaying the diagnosis to a very advanced stage. The differential diagnosis of such a large unilateral soft tissue density include Ewing's sarcoma, rhabdomyosarcoma, neuroblastoma and ganglioneuroblastoma.²

To our knowledge this case is the largest Askin's tumour reported in literature. The tumor size of 27cm × 14.6cm × 15.5 cm of our patient was larger than the previously reported maximum of

15 cm × 22.5 cm.³ The largest tumour in the original series of 20 patients by Askin et al. had the maximum diameter of 14 cm.¹ The maximum size of Askin tumor in a series of 11 patients by Zhang et al.⁴ was 12.5 cm and was 13.7 cm in another series published by Xia et al.² The relatively stable vitals at admission, lack of rib erosion and pleural effusion even with this size of a mass were quite unique to this case.

Histopathology reveals undifferentiated sarcomatous tissue of small round cells with scant eosinophilic cytoplasm, high nuclear/cytoplasmic ratio, small single nucleoli, and a high mitotic rate. Immunohistochemistry is positive for CD99 and neuron specific enolase.⁵ Nowadays diagnosis of Askin's tumour is based on oncogenetics by looking for chromosomal translocations t(11;22)(q24; q12) and/or their fusion transcripts. This mutation is also seen in Ewing's Sarcoma. The prognosis of this tumour remains poor due to local recurrence and distant metastasis usually to lungs and skeletal system.³ The factors which determine the prognosis include size of the primary tumor, Serum Lactate dehydrogenase (LDH) levels, distant metastasis and performance score of the patient. Unfortunately, our patient with such a huge mass succumbed to her illness shortly after starting chemotherapy.

References

1. Askin FB, Rosai J, Sibley RK, Dehner LP, Mc Alister WH: Malignant small cell tumour of the thoracopulmonary region in childhood: a distinctive clinicopathologic entity of uncertain histogenesis. *Cancer* 1979, 43:2438–2451. doi: [10.1002/1097-0142\(197906\)43:6<2438::aid-cncr2820430640>3.0.co;2-9](https://doi.org/10.1002/1097-0142(197906)43:6<2438::aid-cncr2820430640>3.0.co;2-9).
2. Xia T, Guan Y, Chen Y, Li J. Askin tumor: CT and FDG-PET/CT imaging findings and follow-up. *Medicine (Baltimore)*. 2014; 93(6): e42. doi: [10.1097/MD.0000000000000042](https://doi.org/10.1097/MD.0000000000000042).
3. Dou X, Yan H, Wang R. Treatment of an Askin tumor: A case report and review of the literature. *Oncol Lett* 2013; 6:985-989. doi: [10.3892/ol.2013.1488](https://doi.org/10.3892/ol.2013.1488).
4. Zhang KE, Lu R, Zhang P, Shen S, Li X. Askin's tumor: 11 cases and a review of the literature. *Oncol Lett* 2016; 11:253-256. doi: [10.3892/ol.2015.3902](https://doi.org/10.3892/ol.2015.3902).
5. Desai SS, Jambhekar NA. Pathology of Ewing's sarcoma/PNET: Current opinion and emerging concepts. *Indian J Orthop*. 2010; 44:363-368. doi: [10.4103/0019-5413.69304](https://doi.org/10.4103/0019-5413.69304).

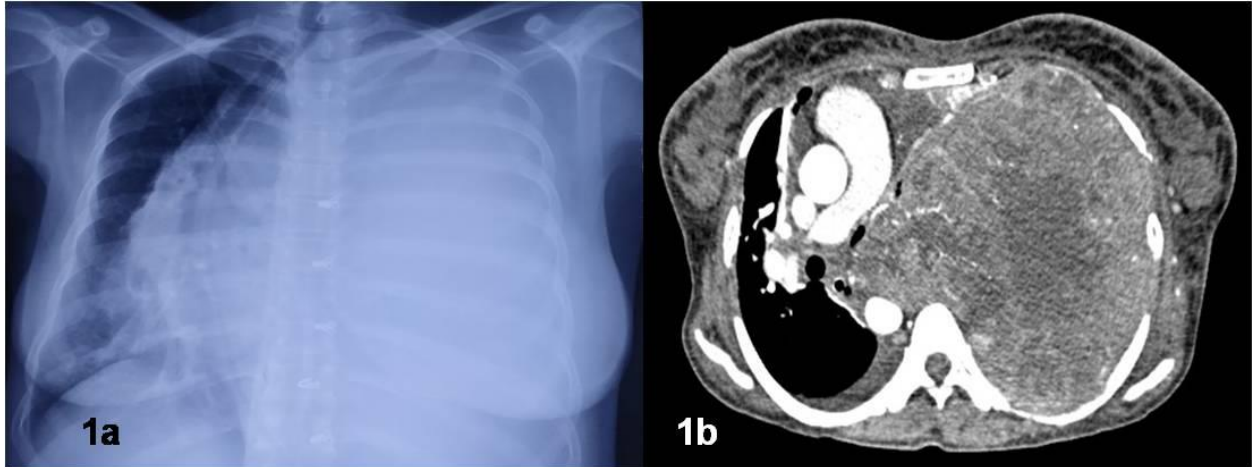


Figure 1: A: Chest Radiography showing whiteout left hemithorax and gross contralateral shifting of mediastinal structures. **B:** CT Thorax (mediastinal window) at level T-5 showing a huge mass lesion virtually replacing left lung and gross contralateral shifting of mediastinum. The mass lesion has various necrotic areas interspersed in between.

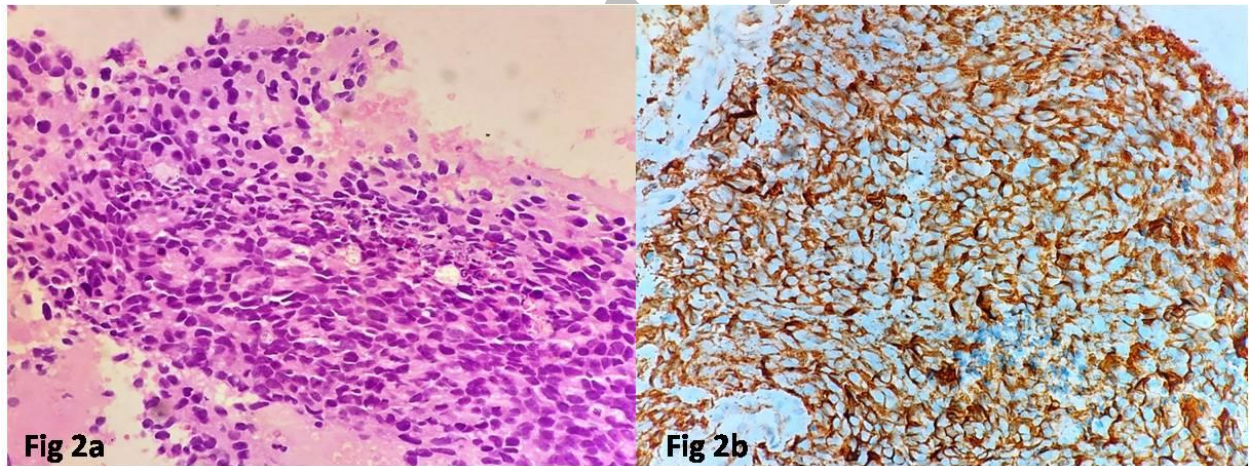


Figure 2: A: USG guided biopsy showed a hypercellular tumour lying in sheets composed of small, round, hyperchromatic tumour cells with scant cytoplasm. At some places tumour cells are seen encircling lumen forming rosettes (H&E; X 200). **B:** The tumour cells showed strong membranous positivity on immunostaining with CD99 (CD99; X200).