

# Acquired Uterine Vascular Anomaly

## Experience from a tertiary care centre in Pakistan

Kulsoom Fatima,<sup>1</sup> Mustafa B.A. Zubairi,<sup>2</sup> Muhammad Azeemuddin,<sup>1</sup> \*Raza Sayani<sup>1</sup>

**ABSTRACT: Objectives:** This study aimed to retrospectively review imaging findings and the outcomes of uterine artery embolisation (UAE) in symptomatic uterine vascular anomalies (UVA). **Methods:** This study included a total of 15 patients with acquired UVA admitted to the Aga Khan University Hospital in Karachi, Pakistan, from 2010 to 2020. These patients were evaluated using ultrasound, computed tomography and magnetic resonance imaging, either alone or in combination. All patients had a history of dilatation and curettage or uterine instrumentation and underwent angiography and embolisation of the uterine arteries. The primary outcome post embolisation was assessed clinically and/or in combination with ultrasound. Post-procedure pregnancies were also recorded. **Results:** Non-invasive imaging was abnormal in all patients; however, this pre-intervention imaging was unable to accurately classify the type of vascular anomaly, except in the case of a pseudoaneurysm. Conventional angiography showed uterine artery hyperaemia in six patients, arteriovenous malformation in seven patients and pseudoaneurysm in two patients. The technical success rate was 100% and no repeat embolisation was needed. The follow-up ultrasound in 12 patients revealed a resolution of the abnormal findings, while the remaining three were found to be normal on clinical follow-up. Seven patients (46.7%) had a normal pregnancy 15.7 months after the procedure (range: 4–28 months). **Conclusions:** UAE is a safe and effective management option for intractable severe bleeding in patients with UVA post instrumentation and it was found that the procedure does not impair future pregnancy.

**Keywords:** Uterine Artery Embolization; Pseudoaneurysm; Arteriovenous Malformation; Ultrasonography; X-Ray Computed Tomography; Magnetic Resonance Imaging; Pakistan.

### ADVANCES IN KNOWLEDGE

- All hypervascular lesions that are detected upon ultrasound imaging of the uterus are not true arteriovenous malformations.
- The placental subinvolution theory should be considered when assessing patients for suspected uterine vascular anomaly post abortion using imaging.

### APPLICATION TO PATIENT CARE

- Pelvic artery embolisation prevents hysterectomy in cases of severe vaginal bleeding.
- Embolisation of the uterine artery does not preclude a successful pregnancy in the future.

ACCORDING TO THE CLASSIFICATION SYSTEM of the International Society for the Study of Vascular Anomalies, uterine vascular anomalies (UVAs) are classified into two main types: (i) vascular malformations and (ii) vascular neoplasms.<sup>1</sup> The first category includes several entities such as venous malformations, arteriovenous fistulas, pseudoaneurysms, arteriovenous malformations (AVMs) and rarely, a combination of a pseudoaneurysm and AVM.<sup>1–3</sup> AVMs are the most frequently reported UVA, although their true incidence is unknown.<sup>4,5</sup> These may either be congenital or acquired, the latter being far more common.<sup>4,6</sup> Acquired uterine AVMs lack a true *nidus* and are most commonly observed secondary to uterine trauma due to curettage or uterine surgery, which results in abnormal communication of uterine artery branches with the myometrial venous plexus.<sup>4,7,8</sup>

Rare causes of uterine AVM include endometrial or cervical carcinoma, leiomyoma, uterine infection,

gestational trophoblastic diseases or endometriosis.<sup>8–10</sup> Direct communication between the artery and vein results in arteriovenous fistulas.<sup>1,11</sup> Pseudoaneurysms constitute another rare acquired vascular anomaly. These are focal areas of confined defects that lack a true wall and communicate with the vessel lumen. Frequently, they form as a result of a trauma due to pelvic/uterine surgery or a curettage procedure.<sup>2</sup> Patients with acquired UVA present with acute heavy bleeding, which may be intermittent or continuous.<sup>5</sup> Other symptoms include lower abdominal pain, urinary frequency or incontinence, dyspareunia and hypotension or hypovolemia secondary to blood loss.<sup>10</sup> All patients with suspected uterine AVM initially undergo ultrasound evaluation for diagnosis, supplemented by computed tomography (CT) or magnetic resonance imaging (MRI) in cases where an ultrasound is inconclusive.<sup>11</sup> Although conventional angiography is the gold standard for diagnosis, it is reserved for patients that are unresponsive to

<sup>1</sup>Department of Radiology, Aga Khan University Hospital and <sup>2</sup>Medical College, Dow University of Health Sciences, Karachi, Pakistan

\*Corresponding Author's e-mail: [sayani\\_raza@yahoo.com](mailto:sayani_raza@yahoo.com)

conservative management and when a therapeutic embolisation is planned.<sup>12–15</sup>

The purpose of the present study was to review the diagnostic accuracy of imaging in identifying UVAs in a cohort of symptomatic patients and to assess the technical success of percutaneous uterine artery embolisation (UAE) in its management.

## Methods

The present study was conducted as a retrospective analysis at the Aga Khan University Hospital (AKUH), Karachi, Pakistan. Patients who underwent UAE from January 2010 to May 2020 were identified from the radiology database of the hospital. After excluding patients with known uterine tumours, retained products of conception, gestational trophoblastic disease and postpartum haemorrhage, 15 cases were identified in which UVAs were suspected clinically and/or on imaging.

A pre-structured pro forma was used to record patient demographics, including age, parity, pattern and volume of vaginal bleeding, history of uterine surgery or dilatation and curettage (D&C), time interval since the intervention, findings on imaging and angiography and patient outcome. The duration of hospital stays, post-procedure complication, follow-up ultrasound findings and post-embolisation fertility/pregnancy were also recorded. The patients' imaging was reviewed using the picture archiving and communication system, Rogan Delft View Pro-X (Rogan-Delft BV, Veenendaal, Utrecht, Netherlands), while additional data was collected from the Health Information Management Services.

The pre-angiography imaging modality was chosen at the discretion of the referring physician and included ultrasonography with colour Doppler imaging, pelvic MRI and CT, either by itself or in combination. The referring physician decided on embolisation after consultation with the interventional radiologist who performed the embolisation procedures in the angiographic suite of the present hospital.

The patients underwent the procedure on a flat panel monoplane digital subtraction angiography machine, Axiom-Artis (Siemens Healthineers, Erlangen, Germany), under local anaesthesia. The femoral artery was punctured and a 4F vascular access sheath was inserted. A 4Fr Simmons 1 catheter (Cordis, Santa Clara, California, USA) or a Cobra 1 angiographic catheter (Cordis) was advanced over a 0.035-inch guide wire. An angiographic run was performed after selective catheterisation of the uterine artery. It was followed by super-selective cannulation using a Progreat® microcatheter (Terumo

Interventional Systems, Tokyo, Japan), which was placed coaxially as near as possible to the feeder vessel. The embolisation materials used were polyvinyl alcohol particles (PVA) that were 355–500 µm in size, gel foam, glue and coil, either in combination or in isolation. In a few cases, the ovarian artery was also embolised. Clinical success was defined as the resolution of vaginal bleeding and/or abnormal imaging findings on post-embolisation follow-up.

The Statistical Package for the Social Sciences (SPSS), Version 20.0 (IBM Corp., Armonk, New York, USA) was used for statistical analysis. All quantitative data were expressed as mean ± standard deviation and qualitative data were expressed using frequencies and percentages. A descriptive analysis was conducted for all the variables, including the demographic and the other categorical variables and frequencies, proportions and percentages were reported.

The benefits and risks of the embolisation procedure were explained to the patients and it was performed only after their consent was obtained. Ethical approval for the study was obtained from the Ethical Review Committee of AKUH (ERC #2020-3690-10189).

## Results

The mean patient age was 28.2 years (range: 20–35 years). A total of 14 patients had undergone a prior uterine procedure, 12 had a prior D&C, one had a repair of a uterine rupture and one had a C-section. The patient without prior D&C or surgery had a history of medical termination of the pregnancy.

The main presenting complaint was abnormal pervaginal bleeding. It was considered mild in case of only spotting, moderate in case of continuous bleeding without clots and severe in case of passage of clots. The mean time interval of patient presentation following the intervention was 64.6 days (range: 1–365 days) [Table 1].

All patients underwent a pre-embolisation ultrasound except one, who underwent only an MRI examination. The greyscale ultrasound identified an abnormal area in the myometrium in 12 patients (85.7%) and an abnormal area in the endometrium in two patients. On Doppler imaging, eight patients showed mixed arterial/venous flow. Following angiography, six of the eight patients were confirmed to have AVM, while the other two showed only uterine hyperaemia [Figure 1]. Four patients showed focal increased vascularity within the myometrium, one was found to be an AVM on angiography and the remaining three patients only showed uterine artery hyperaemia. Two patients showed pseudoaneurysms on Doppler,

**Table 1:** Baseline characteristics of patients with suspected uterine vascular anomalies (N= 15)

Characteristic	n (%)
Mean age in years (range)	28.2 (20–35)
<b>Parity</b>	
0	3
1–2	7
>3	5
<b>History of D&amp;C</b>	12
Mean time since D&C in days (range)	42.6 (1–60)
History of uterine surgery	2
History of MTP	1
<b>Amount of bleeding</b>	
Moderate	6 (40)
Severe	9 (60)
<b>Pattern of bleeding</b>	
Intermittent	9 (60)
Continuous	6 (40)

D&C = dilatation and curettage; MTP = medical termination of pregnancy.

which were confirmed through a pre-embolisation CT and angiography [Figure 2]. Two other patients had abnormal focal vascularity on arterial phase, with prominent veins on the pre-embolisation CT suggesting AVM. Of these two cases, one proved to be AVM on angiography [Figure 3], while the other showed only uterine hyperaemia.

Six out of the 15 patients underwent pre-embolisation MRI. The MRI findings demonstrated abnormal signal intensity areas in either the myometrium or endometrium, with abnormal enhancement and multiple flow voids suggesting AVM. Three of these were confirmed as AVM on angiography, while the other three showed enlarged, prominent uterine arteries [Figure 4].

The most frequently used embolisation material for the procedure (13 out of the 15 cases) was PVA particles. It was the sole embolic agent in 10 cases, while it was used in combination with gel foam in one case and in combination with histoacryl glue and coil in two other cases. Gel foam was used as the sole embolic agent in one case. One patient with a right uterine artery pseudoaneurysm was embolised with cyanoacrylate glue [Table 2].

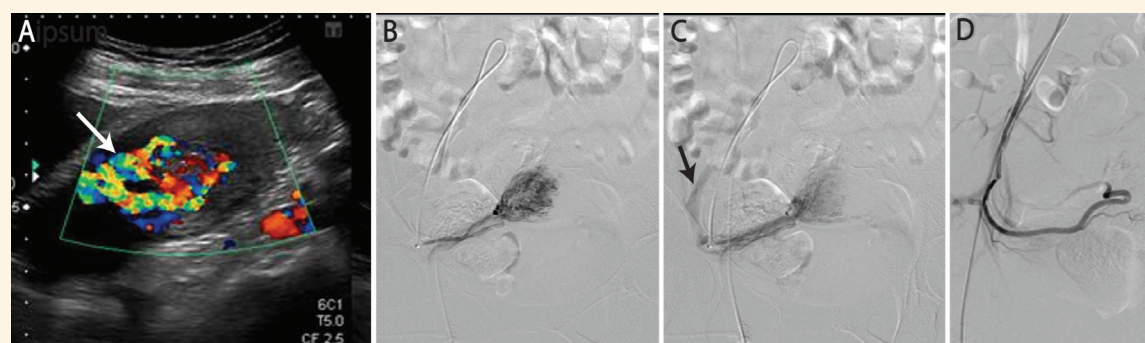
The embolisation procedure was technically successful in all 15 patients, none of whom required a repeat embolisation or post-embolisation transfusion. None of the patients had an on-table procedure-related or puncture site complication. The mean duration of hospital stay was 2.73 days (range: 2–4 days). Nine out of the 15 patients had mild bleeding at the time of discharge from the hospital, which resolved by the next clinic visit. Two patients had an episode of pervaginal bleeding a month later, which resolved in response to conservative management.

A total of 12 patients underwent follow-up ultrasound examinations. The mean time interval for

**Table 2:** Details of the embolisation procedure in patients with suspected uterine vascular anomalies (N= 15)

Case	Angiographic finding	Vessels embolised	Embolisation material used	Complication	Duration of hospital stay	Post-embolisation pregnancy
1	Hyperaemia	B/L uterine artery	PVA	None	2	No
2	Hyperaemia	B/L uterine artery	PVA	None	3	No
3	Hyperaemia	B/L uterine artery	PVA + gel foam	None	2	Yes
4	Hyperaemia	U/L uterine artery	PVA	Fever	3	No
5	Hyperaemia	B/L uterine artery	PVA	None	4	Yes
6	Hyperaemia	B/L uterine artery	PVA	None	4	No
7	AVM	B/L uterine artery	PVA	None	2	No
8	AVM	B/L uterine artery	PVA	None	4	Yes
9	AVM	B/L uterine artery	PVA	None	2	No
10	AVM	B/L uterine artery	Gel foam	None	3	Yes
11	AVM	B/L uterine artery	PVA	Fever	4	Yes
12	AVM	B/L uterine artery	PVA	None	2	No
13	AVM	B/L uterine artery + ovarian	PVA + coil + glue	None	2	No
14	Pseudoaneurysm	U/L uterine artery	Glue	None	2	Yes
15	Pseudoaneurysm	B/L uterine + ovarian	PVA + coil + glue	None	2	Yes

B/L = bilateral; PVA = polyvinyl alcohol; U/L = unilateral; AVM = arteriovenous malformation.



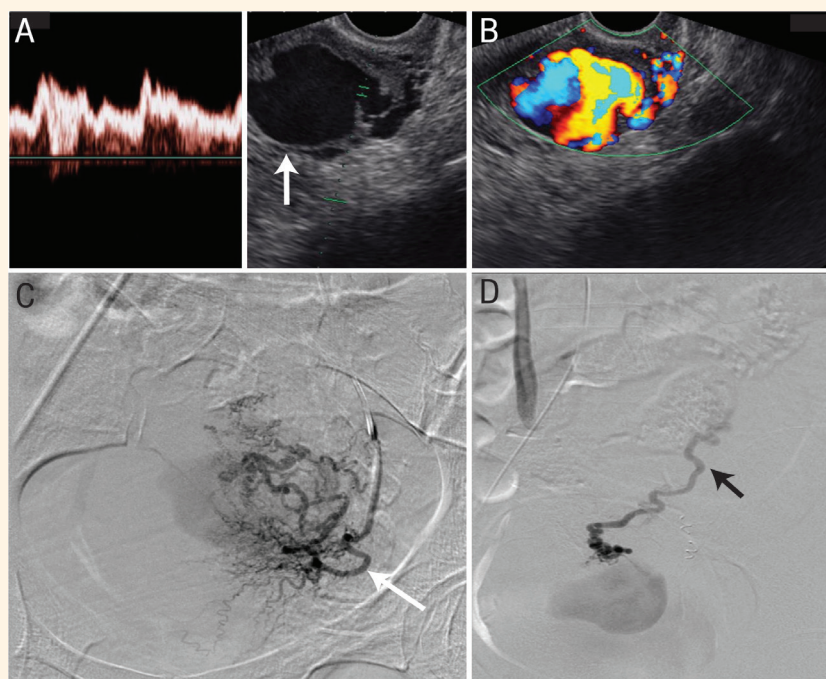
**Figure 1:** Moderate vaginal bleeding in a 25-year-old demonstrated via a (A) Doppler ultrasound showing a mosaic colour pattern in the myometrium on the right side extending into endometrium, indicating both arterial and venous flow (arrow), (B) digital subtraction angiography (DSA) image showing the arteriovenous malformation (AVM) supplied by right uterine artery, (C) DSA image showing the early draining vein (arrow) and (D) Post-embolisation DSA image showing resolution of the AVM.

the follow-up ultrasound was 40.6 days (range: 15–90 days) after embolisation. In five patients, the follow-up ultrasound was completely normal. On the other hand, five patients showed persistent greyscale findings, although the abnormal vascularity had resolved. One patient showed a decrease in size of the abnormal area on ultrasound, with persistent mild vascularity, although she was asymptomatic. In another patient, abnormality was demonstrated on both greyscale and Doppler ultrasound on initial follow-up, but it resolved completely on repeat ultrasound two months later. Three patients did not have any follow-up imaging but were clinically asymptomatic.

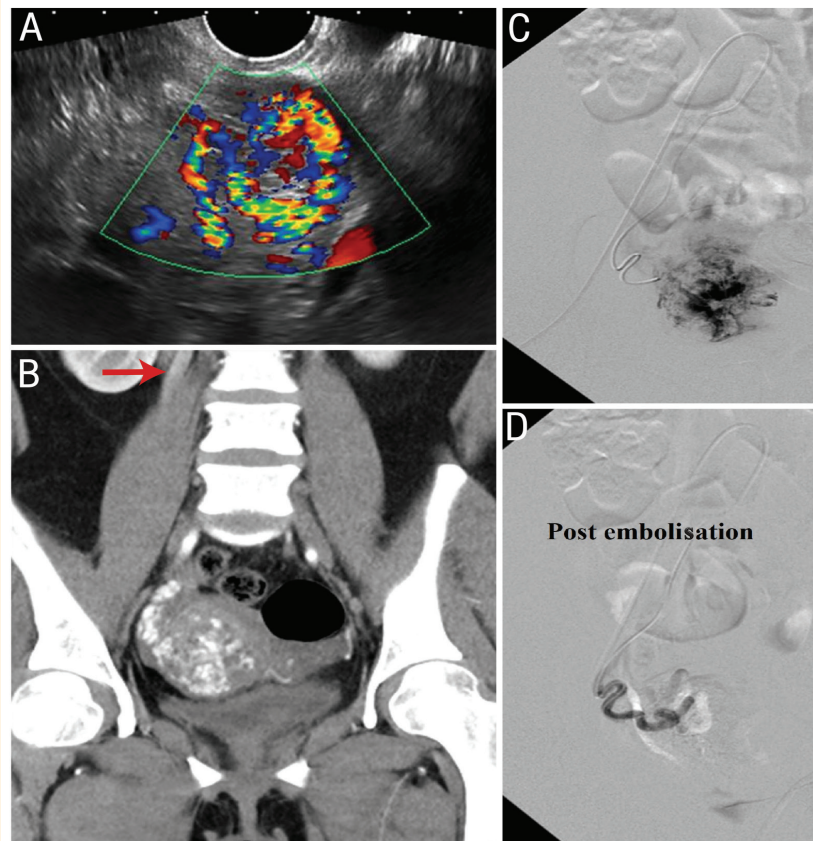
Seven patients (46.7%) had normal pregnancies that were carried to term after the procedure. The mean time interval between the procedure and the pregnancy was 15.7 months (range: 4–28 months). The remaining eight did not conceive to the best of the authors' knowledge.

## Discussion

The present retrospective study conducted at a tertiary referral centre, reviewed a spectrum of imaging findings in patients with suspected acquired UVA. Additionally, the outcomes of super-selective UAE



**Figure 2:** Moderate, post uterine surgery vaginal bleeding in a 29-year-old demonstrated via a (A) greyscale transvaginal ultrasound image showing an irregular anechoic area in the myometrium (arrow) with the turbulent arterial flow on spectral analysis, (B) Doppler image showing heterogeneous colour filling in the pseudoaneurysm and (C and D) digital subtraction angiographic images of left uterine artery (red arrow) and left ovarian artery (black arrow) supplying the pseudoaneurysm.



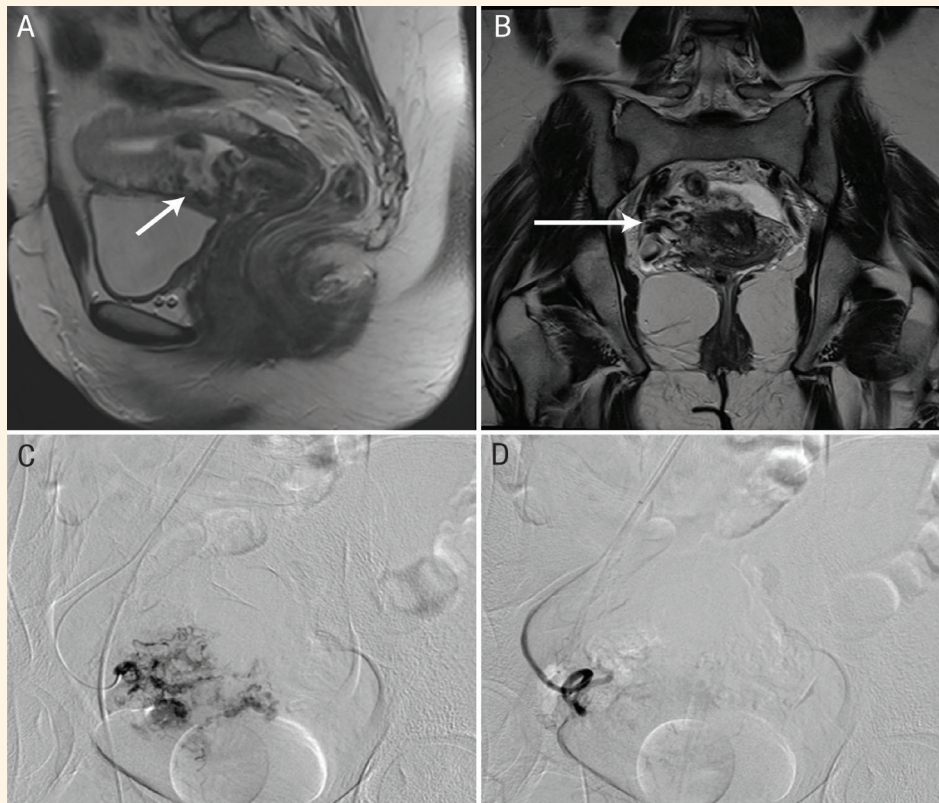
**Figure 3:** Continuous vaginal bleeding in a 25-year-old demonstrated via (A) transvaginal ultrasound Doppler images showing abnormal vascularity in the uterine myometrium, (B) a coronal contrast-enhanced computed tomography image confirming abnormal myometrial vascularity and dilated draining gonadal vein (arrow), (C) a digital subtraction angiography image showing an abnormal bunch of vessels supplied by right uterine artery and (D) a post-embolisation image showing complete resolution of the arteriovenous malformation.

were also studied. True AVMs were observed in seven cases, including one arteriovenous fistula. Additional anomalies observed include uterine hyperaemia and pseudo-aneurysm. Timmerman *et al.* studied 30 cases of suspected uterine vascular malformations, out of which eight underwent angiography.<sup>16</sup> Their study showed true AVMs in three patients, while the rest had only an abnormal arterial blush. Occasionally, the number of AVMs is found to be purportedly higher on (conventional) angiography. Hugues *et al.* studied 26 cases of suspected uterine AVMs, of which about a quarter showed uterine hyperaemia, while true AVMs were observed in the remaining cases.<sup>17</sup> Furthermore, a study of iatrogenic uterine arterial injuries, which were treated by UAE, found AVMs in the majority of cases (15 out of 24), either alone or in combination with a pseudoaneurysm.<sup>2</sup>

All of the cases considered in the present study showed abnormalities on both greyscale and colour Doppler ultrasound examinations. The two cases of pseudoaneurysms were accurately identified. Pseudoaneurysms appear as cystic spaces on greyscale ultrasound and exhibit swirling multidirectional flow on colour Doppler, with varying degrees of turbulence;

hence they allow for accurate identification in most cases.<sup>12</sup> The greyscale appearances of AVMs, on the other hand, are non-specific, ranging from subtle myometrial inhomogeneity to linear, anechoic spaces in the myometrium, which show colour filling on Doppler interrogation with a mosaic pattern.<sup>12,19</sup> The specificity is increased by duplex ultrasound/spectral analysis that reveals high-velocity and low-resistance arterial flow.<sup>16</sup>

Unfortunately, the spectral analysis findings were not available in all the cases considered for the present study as mostly only greyscale and colour Doppler evaluations were conducted. It has been observed that low-resistance abnormal vascularity often persists in the myometrium at the site of trophoblast or placental implantation and takes time to resolve.<sup>1,10</sup> This is referred to as sub-involution of the placental bed and may account for abnormal findings on ultrasound and MRI, as observed in some of the patients included in the present study who subsequently demonstrated only uterine hyperaemia on angiography with no AVM. Nevertheless, angioembolisation was justified since these patients presented with moderate to severe bleeding that had been resistant to conservative



**Figure 4:** Severe vaginal bleeding in a 31-year-old demonstrated via a (A) T2 weighted sagittal magnetic resonance image showing a heterogeneous bulging mass with serpentine signal voids involving the lower uterine cavity and anterior myometrium (arrow), where no myometrium is seen between the urinary bladder and this mass, (B) coronal T2 weighted image showing multiple serpentine signal voids (arrow), (C) digital subtraction angiographic image showing dilated tortuous right uterine artery supplying arteriovenous malformation (AVM) and (D) post-embolisation image showing complete resolution of the AVM.

management. The symptoms resolved completely following a single session of embolisation with no discernible adverse effects.

Although digital subtraction angiography (DSA) is currently the gold standard for the diagnosis of UVA, its use is not justified unless DSA is utilised as the precursor to an embolisation. The management of UVAs depends on the clinical presentation as well as the severity of the anomaly. Patients who show minimal symptoms and/or are haemodynamically stable may be followed-up clinically and by ultrasound. Bleeding usually resolves spontaneously within weeks to months in milder cases.<sup>19</sup> UAE is offered to patients with severe intractable or recurrent bleeding. It helps to avoid hysterectomy, thereby preserving chances of future fertility. UAE may theoretically result in reduced vascular supply to the uterus; however, the presence of rich collaterals prevents uterine infarction.<sup>12</sup> Many case reports and studies have shown successful pregnancy outcomes post angioembolisation.<sup>12,19,20</sup> Almost half of the cases considered in the present study had post-embolisation pregnancies that were carried to term.

It is known that the reported complication rate of pelvic artery embolisation is low.<sup>21</sup> Several embolic

agents have been used for the treatment of UVAs, including gel foam, PVA particles, glue, coil or a combination of these agents.<sup>12,14,15,17,21,22</sup> In the present study, PVA particles were the most frequently used embolisation material, employed in 13 out of the 15 cases.

Minor complications such as puncture site pain or haematoma, fever and transient lower limb and buttock claudication are more frequent than severe complications such as iatrogenic rupture of a pelvic artery, sloughing of perineal skin, vesicovaginal fistula or major distal ischemia.<sup>12,21,22</sup> No major post-procedural complications were encountered in the present study. Only three patients experienced mild abdominal pain, which did not require any treatment, while fever was observed in two patients, which resolved before discharge.

## Conclusion

Ultrasound is the first-line imaging modality employed for the diagnosis of UVAs. It has high specificity for pseudoaneurysms but lacks specificity for AVMs. It is important to consider placental bed sub-involution

when diagnosing AVMs on non-invasive imaging among patients with a history of a recent miscarriage. The findings from the current study demonstrate that UAE is a safe and effective management option for intractable severe bleeding in patients with UVAs post instrumentation and it does not appear to limit future pregnancy outcomes.

#### AUTHORS' CONTRIBUTION

KF, RS and MA were involved in conceptualisation of the idea. KF and MZ collected the data. KF, MZ and RS analysed and interpreted the data and drafted the manuscript. MA critically reviewed the manuscript and supervised the study. All authors approved the final version of this manuscript.

#### CONFLICT OF INTEREST

The authors declare no conflict of interest.

#### FUNDING

No funding was received for this study.

## References

1. Vijayakumar A, Srinivas A, Chandrashekar BM, Vijayakumar A. Uterine vascular lesions. *Rev Obstet Gynecol* 2013; 6:69–9.
2. Kwon JH, Kim GS. Obstetric iatrogenic arterial injuries of the uterus: Diagnosis with US and treatment with transcatheter arterial embolisation. *Radiographics* 2002; 22:35–46. <https://doi.org/10.1148/radiographics.22.1.g02ja0735>.
3. Mammen T, Shanthakumari H, Gopi K, Lionel J, Ayyappan AP, Kekre A. Iatrogenic secondary post-partum haemorrhage: Apropos of two uncommon cases. *Australas Radiol* 2006; 50:392–4. <https://doi.org/10.1111/j.1440-1673.2006.01609.x>.
4. O'Brien P, Neyastani A, Buckley AR, Chang SD, Legiehn GM. Uterine arteriovenous malformations: From diagnosis to treatment. *J Ultrasound Med* 2006; 25:1387–92. <https://doi.org/10.7863/jum.2006.25.11.1387>.
5. Kim TH, Lee HH. Presenting features of women with uterine arteriovenous malformations. *Fertil Steril* 2010; 94:2330.e7–10. <https://doi.org/10.1016/j.fertnstert.2010.03.031>.
6. Vogelzang RL, Nemcek AA Jr, Skrtic Z, Gorrell J, Lurain JR. Uterine arteriovenous malformations: Primary treatment with therapeutic embolisation. *J Vasc Interv Radiol* 1991; 2:517–22. [https://doi.org/10.1016/s1051-0443\(91\)72234-3](https://doi.org/10.1016/s1051-0443(91)72234-3).
7. Hoffman MK, Meilstrup JW, Shackelford DP, Kaminski PF. Arteriovenous malformations of the uterus: An uncommon cause of vaginal bleeding. *Obstet Gynecol Surv* 1997; 52:736–40. <https://doi.org/10.1097/00006254-199712000-00004>.
8. Fleming H, Ostör AG, Pickel H, Fortune DW. Arteriovenous malformations of the uterus. *Obstet Gynecol* 1989; 73:209–14.
9. Cockshott WP, Hendrickse JP. Persistent arteriovenous fistulae following chemotherapy of malignant trophoblastic disease. *Radiology* 1967; 88:329–33. <https://doi.org/10.1148/88.2.329>.
10. Timmerman D, Van den Bosch T, Peeraer K, Debrouwere E, Van Schoubroeck D, Stockx L, et al. Vascular malformations in the uterus: Ultrasonographic diagnosis and conservative management. *Eur J Obstet Gynecol Reprod Biol* 2000; 92:171–8. [https://doi.org/10.1016/s0301-2115\(00\)00443-7](https://doi.org/10.1016/s0301-2115(00)00443-7).
11. Polat P, Suma S, Kantarcý M, Alper F, Levent A. Color Doppler US in the evaluation of uterine vascular abnormalities. *Radiographics* 2002; 22:47–53. <https://doi.org/10.1148/radiographics.22.1.g02ja0947>.
12. Ghai S, Rajan DK, Asch MR, Muradali D, Simons ME, TerBrugge KG. Efficacy of embolisation in traumatic uterine vascular malformations. *J Vasc Interv Radiol* 2003; 14:1401–8. <https://doi.org/10.1097/01.rvi.0000096761.74047.7d>.
13. Lin AC, Hung YC, Huang LC, Chiu TH, Ho M. Successful treatment of uterine arteriovenous malformation with percutaneous embolisation. *Taiwan J Obstet Gynecol* 2007; 46:60–3. [https://doi.org/10.1016/S1028-4559\(08\)60109-6](https://doi.org/10.1016/S1028-4559(08)60109-6).
14. Salazar GM, Petrozza JC, Walker TG. Transcatheter endovascular techniques for management of obstetrical and gynecologic emergencies. *Tech Vasc Interv Radiol* 2009; 12:139–47. <https://doi.org/10.1053/j.tvir.2009.08.007>.
15. Kim T, Shin JH, Kim J, Yoon HK, Ko GY, Gwon DI, et al. Management of bleeding uterine arteriovenous malformation with bilateral uterine artery embolisation. *Yonsei Med J* 2014; 55:367–73. <https://doi.org/10.3349/ymj.2014.55.2.367>.
16. Timmerman D, Wauters J, Van Calenbergh S, Van Schoubroeck D, Maleux G, Van Den Bosch T, et al. Color Doppler imaging is a valuable tool for the diagnosis and management of uterine vascular malformations. *Ultrasound Obstet Gynecol* 2003; 21:570–7. <https://doi.org/10.1002/uog.159>.
17. Hugues C, Le Bras Y, Coatleven F, Brun JL, Trillaud H, Grenier N, et al. Vascular uterine abnormalities: Comparison of imaging findings and clinical outcomes. *Eur J Radiol* 2015; 84:2485–91. <https://doi.org/10.1016/j.ejrad.2015.10.005>.
18. Müngen E. Vascular abnormalities of the uterus: Have we recently over-diagnosed them? *Ultrasound Obstet Gynecol* 2003; 21:529–31. <https://doi.org/10.1002/uog.163>.
19. Poppe W, Van Assche FA, Wilms G, Favril A, Baert A. Pregnancy after transcatheter embolisation of a uterine arteriovenous malformation. *Am J Obstet Gynecol* 1987; 156:1179–80. [https://doi.org/10.1016/0002-9378\(87\)90136-0](https://doi.org/10.1016/0002-9378(87)90136-0).
20. Chow TW, Nwosu EC, Gould DA, Richmond DH. Pregnancy following successful embolisation of a uterine vascular malformation. *Br J Obstet Gynaecol* 1995; 102:166–8. <https://doi.org/10.1111/j.1471-0528.1995.tb09075.x>.
21. Sidhu HK, Prasad G, Jain V, Kalra J, Gupta V, Khandelwal N. Pelvic artery embolisation in the management of obstetric hemorrhage. *Acta Obstet Gynecol Scand* 2010; 89:1096–9. <https://doi.org/10.3109/00016349.2010.481015>.
22. Grönvall M, Tikkanen M, Metsätähti M, Loukovaara M, Paavonen J, Stefanovic V. Pelvic arterial embolisation in severe obstetric hemorrhage. *Acta Obstet Gynecol Scand* 2014; 93:716–9. <https://doi.org/10.1111/aogs.12376>.