

# A Central Venous Catheter Line Misadventure

“Doctor why do I have a humming sound in my ear?”

\*Edwin Stephen,<sup>1</sup> Maitha Al Asmi,<sup>1</sup> Thekra Al Hadhrami,<sup>1</sup> Mohsin Al Riyami,<sup>2</sup> Mohammed Al Badri,<sup>3</sup> Hanan Al Mawaali,<sup>1</sup> Khalifa Al Wahaibi<sup>1</sup>

**ABSTRACT:** We report a 32-year-old female patient who was referred to a tertiary care hospital in Muscat, Oman, in 2021 with an iatrogenic arteriovenous fistula (AVF) that presented as a neck swelling which developed few weeks after an attempt of central venous catheterisation through the right internal jugular vein. The fistula was corrected surgically with a successful outcome. AVF is an abnormal communication between an artery and vein which can occur as a congenital anomaly, after trauma or iatrogenic following central venous catheter or endovenous thermal ablation.

**Keywords:** Arteriovenous Fistula; Iatrogenic Disease; Central Venous Catheter; Critically Ill; Intensive Care Unit; Case Report; Oman.

**A**N ARTERIOVENOUS FISTULA (AVF) IS AN abnormal communication between an artery and vein. It can occur as a congenital anomaly or iatrogenic during any arterial or venous instrumentation, trauma or endovenous thermal ablation.<sup>1,2</sup> One of the earliest cases of iatrogenic AVF was published by James and Myers in 1972.<sup>3</sup> The incidence of iatrogenic AVFs has previously been described to be less than 0.6% of central line insertions.<sup>4</sup> However, the introduction of ultrasound guidance causes reduction in the incidence.<sup>5</sup> This case report describes an iatrogenic AVF that presented as a neck swelling that developed several weeks after an attempt of central venous catheterisation through the internal jugular vein (IJV).

## Case Report

We report a 32-year-old female patient who presented to a tertiary care hospital in Muscat, Oman, in 2021. She was admitted earlier to the intensive care unit with an impression of sepsis, hypotension with multiorgan failure and acute kidney injury. The patient was haemodynamically unstable at presentation to the center where she was managed; therefore, a central venous catheter (CVC) insertion was attempted through the right IJV for haemodialysis under ultrasound guidance. As the dilator was not traversing freely, the procedure was abandoned, pressure applied and a femoral Quinton line inserted. Several days after discharge, the patient developed a swelling on the right-side of the neck associated with a humming sound in her right ear and a thrill; she didn't have coagulation abnormalities, so she was referred to the current centre to rule out iatrogenic AVF and treat the patient accordingly.

On examination, the patient had a pulsatile swelling that was 3 × 4 cm in size, with a thrill and a bruit on the right-side of the neck between sternal head of sternocleidomastoid, clavicular head of sternocleidomastoid and the clavicle. Neurological examination was normal and pulses were intact. Duplex ultrasound was performed and a fistula was seen between the right IJV and the right common carotid artery (CCA). The IJV was pulsatile in the region of the fistula and it showed a focal dilation. A computed tomography angiography (CTA) was performed and it showed an arteriovenous fistulous communication between the right CCA and IJV [Figure 1].

The patient underwent surgical closure of the iatrogenic AVF; an incision along the lateral border of the neck anterior to the sternocleidomastoid muscle was performed. A 4 mm mature neck between the right IJV and CCA was found [Figure 2]. The fistula was divided between vascular clamps and repaired directly on the venous and arterial side with 6-0 prolene sutures [Figures 3 and 4]. CCA was not clamped during surgery; she had normal left CCA and intracranial circulation, therefore, cerebrovascular monitoring was not considered.

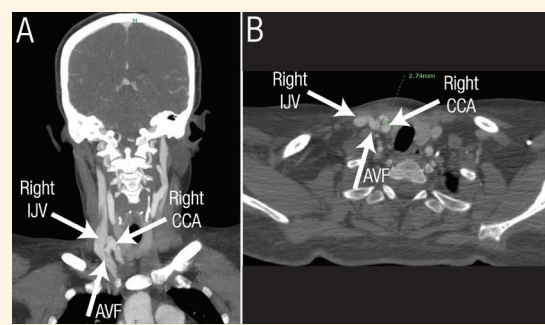
Postoperatively, the patient was neurologically normal, the thrill and bruit on the neck disappeared. At follow-up four weeks postoperatively, she remained well. Patient consent was obtained for publication purposes.

## Discussion

Catheterisation of the IJV is commonly done for temporary haemodialysis, compared to subclavian and femoral access, as it is considered a safer option.<sup>6</sup> In the

<sup>1</sup>Vascular Surgery Unit, <sup>2</sup>Division of Surgery, Sultan Qaboos University Hospital, Muscat, Oman; <sup>3</sup>General Surgery, Oman Medical Specialty Board, Muscat, Oman

\*Corresponding Author's e-mail: [edwinmay2013@gmail.com](mailto:edwinmay2013@gmail.com)

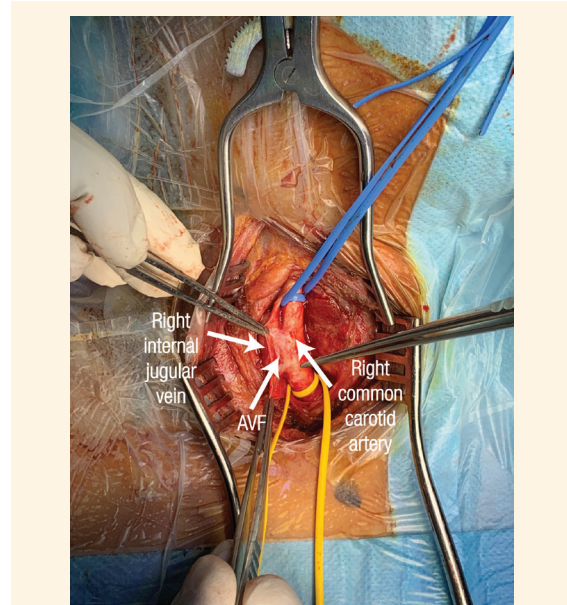


**Figure 1:** Computed tomography angiography showing the (A) coronal view of the right internal jugular vein (IJV)-common carotid artery (CCA) fistula and the (B) axial view showing a right IJV-CCA fistula.

AVF = arteriovenous fistula.

experience of the senior authors, an IJV access is the preferred route for a CVC insertion, as a Trendelenburg position is often used in haemodynamically unstable patients. However, femoral access has been used when access to the IJV is not possible, usually due to airway control of cases of maxilla-facial surgery/trauma.

IJV catheterisation can lead to several complications including venous perforation, puncture of the CCA, pneumothorax, cardiac tamponade and Horner's syndrome.<sup>7-10</sup> Literature mentions that valve incompetence in the IJV could impair cerebral venous drainage.<sup>11</sup> Another rare complication of IJV catheterisation is traumatic CCA-IJV fistula (CJF).<sup>2</sup> Traumatic CJF has an incidence of 4-7% of all traumatic AVFs and it can be iatrogenic or due to penetrating injuries such as gunshots or stab injuries.<sup>2</sup> Although it is considered a rare entity, there are several cases reported and published where an iatrogenic AVF was created by central venous catheterisation of the IJV.<sup>2,6,12,13</sup> If left untreated, it can lead to further serious life-threatening complications such as embolisation, infection and at later stages high-output cardiac failure.<sup>2</sup> Therefore, early detection and intervention is

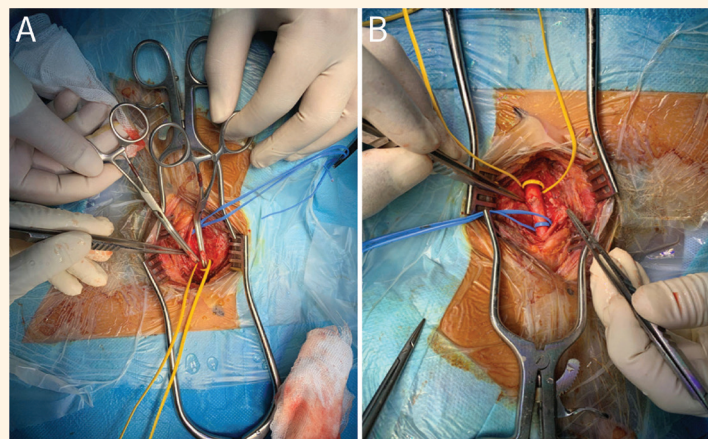


**Figure 2:** Intraoperative photograph showing the identification of the internal jugular vein-common carotid artery fistula.

crucial to prevent such consequences.

Several techniques have been described to reduce the rate of complications during IJV cannulation which include: cannulation under ultrasound guidance, locating the vein using a needle with a smaller gauge, reducing head rotation to less than 40° as this reduces overlap between the vein and artery and using an alternative access if there's difficulty during cannulation.<sup>5,10</sup>

There are various modalities that can be used to diagnose iatrogenic AVF including duplex, magnetic resonance angiography (MRA) and CTA. Duplex imaging in AVF shows an arterialised enlarged vein, high flow fistulous communication and a low resistance waveform of the artery involved.<sup>11</sup> This has an advantage of being fast. CTA and MRA provide a better anatomical view of the vascular injury, such as



**Figure 3:** Intraoperative photograph showing A: the division of the fistula and B: post-repair of the fistula.

the size, type and region, which aids in choosing the best treatment modality.<sup>14</sup>

The treatment options for iatrogenic AVFs are open surgery, endovascular stenting or embolisation. A complex AVF fistula has multiple draining vessels and a complex anatomy, therefore it is better treated with endovascular embolisation or stent grafting.<sup>11</sup> Embolisation of traumatic or iatrogenic AVF's can be offered if the communication is from side branches and not for end arteries.<sup>15</sup> Furthermore, it can be done with Coils, cyanoacrylate glue or Onyx (Covidien, Mansfield, Massachusetts, USA).<sup>11</sup> In the current patient, the CJF was not complex and it was superficial, hence an open surgical approach was preferred.

## Conclusion

Iatrogenic AVF is a rare complication of central venous catheterisation, but it can have serious outcomes. To prevent such outcomes, CVC insertion and other procedures should be carefully performed i.e. under ultrasound-guidance, by experienced personnel and/or skilled supervision. It is important to detect and treat iatrogenic AVF early to prevent more severe complications such as embolisation, infection, atrial fibrillation and, at later stages, high-output cardiac failure. This case report aims to sensitise medical professionals about avoiding iatrogenic CVC misadventures and how they can be managed.

## AUTHORS' CONTRIBUTION

MAA, TAH, MAB, MAR, HAM and ES were involved in the literature review process. ES was responsible for the concept of this manuscript. All authors were involved in drafting the manuscript and all approved the final version of the manuscript.

## References

1. Al Mahruqi G, Stephen E, Abdelhedy I, Al Mawaali H, Al Musalhi B, Al Balushi Z, et al. Congenital vascular malformations: A quick recap. *Oman Med J* 2022; 37:e347. <https://doi.org/10.5001/omj.2021.46>.

2. Sinha VK, Yaduvanshi A, Kataria V, Nair M. Traumatic common carotid-internal jugular arteriovenous fistula manifesting as life-threatening epistaxis. *JACC Case Rep* 2019; 1:576–8. <https://doi.org/10.1016/j.jaccas.2019.08.023>.
3. James PM Jr, Myers RT. Central venous pressure monitoring: Misinterpretation, abuses, indications and a new technic. *Ann Surg* 1972; 175:693–701. <https://doi.org/10.1097/0000658-197205000-00009>.
4. Hansbrough JF, Narrod JA, Rutherford R. Arteriovenous fistulas following central venous catheterization. *Intensive Care Med* 1983; 9:287–9. <https://doi.org/10.1007/BF01691257>.
5. Stephen E, Salins SR, Abdelhedy I, AlBusaidi M, AlHashim AH, AlSukaiti R, et al. Step-by-step guide to averting and managing a central line insertion misadventure. *Indian J Vasc Endovasc Surg* 2020; 7:158–63. [https://doi.org/10.4103/ijves.ijves\\_90\\_19](https://doi.org/10.4103/ijves.ijves_90_19).
6. el-Shahawy MA, Khilnani H. Carotid-jugular arteriovenous fistula: A complication of temporary hemodialysis catheter. *Am J Nephrol* 1995; 15:332–6. <https://doi.org/10.1159/000168859>.
7. Galbert MW, Kay JE. Perforation of the right innominate vein by central venous polyethylene catheter. *Br J Anaesth* 1971; 43:713–14. <https://doi.org/10.1093/bja/43.7.713>.
8. Arnold S, Feathers RS, Gibbs E. Bilateral pneumothoraces and subcutaneous emphysema: A complication of internal jugular venepuncture. *Br Med J* 1973; 1:211–12. <https://doi.org/10.1136/bmj.1.5847.211>.
9. Patel RB. Dialysis catheter-induced pericardial tamponade. *Arch Intern Med* 1983; 143:181–2. <https://doi.org/10.1001/archinte.1983.00350010193042>.
10. Cohen O, Ayalon A, Durst AL. Horner's syndrome: A complication of internal jugular vein cannulation. *Infusionsther Klin Ernahr* 1980; 7:317–18. <https://doi.org/10.1159/000221135>.
11. Patel R, Nicholson A. Arteriovenous Fistulas: Etiology and Treatment. Important considerations from initial evaluation to treatment planning. From: <https://evtoday.com/articles/2012-apr/arteriovenous-fistulas-etiology-and-treatment> Accessed: Dec 2021.
12. Erkut B, Becit N, Kaygin MA, Velioğlu Y. Iatrogenic arteriovenous fistula between the common carotid artery and internal jugular vein: A case report. *EJVES Extra* 2005; 10:74–6. <https://doi.org/10.1016/j.ejvsextra.2005.07.001>.
13. Caldarelli C, Biricotti M, Materazzi G, Spinelli C, Spisni R. Acquired carotid-jugular fistula: Its changing history and management. *ISRN Vascular Med* 2013; 2013:1–8. <https://doi.org/10.1155/2013/320241>.
14. Mahajan A, Luther A. Acquired arteriovenous fistulae: A study of three cases and review of literature. *Indian J Vasc Endovasc Surg* 2016; 3:125–7. <https://doi.org/10.4103/0972-0820.191491>.
15. Franz RW, Jump MA. Endovascular repair of post-traumatic, concomitant popliteal artery pseudoaneurysm and arteriovenous fistula. *Int J Angiol* 2009; 18:41–4. <https://doi.org/10.1055/s-0031-1278322>.