

Radiologic Assessment of Orbital Dimensions among Omani Subjects

A computed tomography imaging-based study at a single tertiary centre

Eiman Al Ajmi,¹ Marwa Al Subhi,⁴ Mallak Al Maamari,² Humoud Al Dhuhli,¹ *Srinivasa R. Sirasanagandla³

ABSTRACT: Objectives: This study aimed to determine the orbital dimensions of Omani subjects who had been referred for computed tomography (CT) of the brain at Sultan Qaboos University Hospital, Muscat, Oman. Good knowledge of the normal orbital dimensions is clinically essential for successful surgical outcomes. Racial, ethnic and regional variations in the orbital dimensions have been reported. **Methods:** A total of 273 Omani patients referred for CT scans of the brain were retrospectively evaluated using an electronic medical records database. The orbital dimensions were recorded using both axial and sagittal planes of CT images. **Results:** The mean orbital index (OI) was found to be 83.25 ± 4.83 mm and the prevalent orbital type was categorised as the mesoseme. The mean orbital index was 83.34 ± 5.05 mm and 83.16 ± 4.57 mm in males and females, respectively, with their difference not being statistically significant ($P = 0.76$). However, a statistically significant association was observed between the right and left orbits regarding horizontal distance ($P < 0.05$) and vertical distance ($P < 0.01$) of orbit and OI ($P < 0.05$). No significant difference between the OI and age groups was observed in males and females. The mean interorbital distance and interzygomatic distance were found to be 19.45 ± 1.52 mm and 95.59 ± 4.08 mm, respectively. These parameters were significantly higher in males ($P < 0.05$). **Conclusion:** Results of the present study provide reference values of orbital dimensions in Omani subjects. Mesoseme, a hallmark of Caucasian people, is discovered to be the prevalent orbital type of Omani subjects.

Keywords: Computed tomography; Ethnicity; Orbit; Biological Variation; Hypertelorism; Oman.

ADVANCES IN KNOWLEDGE

- Results of the present study provide reference values of orbital dimensions in Omani subjects.
- The prevalent orbital type of Omani subjects is the mesoseme, a hallmark of the Caucasian race.

APPLICATION TO PATIENT CARE

- The reference values of orbital dimensions, including orbital index, interorbital distance and interzygomatic distance, reported in this study are essential for diagnosing and treating various orbital pathologies.
- These values are also crucial for surgical corrections of craniofacial anomalies such as orbital hypertelorism, hypotelorism and orbital clefts.

THE BONY ORBIT OR ORBITAL CAVITY IS a complex anatomical region of the facial skeleton. The orbit and its contents are affected by various diseases and craniofacial anomalies such as orbital hypertelorism, hypotelorism and orbital clefts.^{1–3} The majority of orbital diseases and craniofacial anomalies require a thorough knowledge of the normal orbital dimensions in order to diagnose and treat them effectively. Previously, many studies have enumerated the reference values of orbital dimensions among different populations.^{1,4,5} These studies reported a significant variation in orbital dimensions depending on the race and ethnicity of the population. Generally, the orbit shape differs according to ancestry; rectangular orbits are present in Africans, angular orbits in Northern and Southern Europeans and round orbits in Central Asians and Central Europeans.⁶ In most circumstances, the

breadth of the orbital cavity is greater than the height and the orbital index (OI) reflects this relationship. Fernandes *et al.* had developed OI to quantitatively enumerate the orbit size and symmetry for the first time.⁵ OI refers to the proportion of orbital height to the orbital width multiplied by 100. The shape of the face determines the OI of an individual.⁴ Based on different values obtained from previous research, OI is classified into three categories. The first category is megaseme, which indicates a large index and is seen in people of Asian descent. The second category is mesoseme, which indicates intermediate value and is associated with Caucasian people. Finally, microseme, indicating low index value, is characteristic of black people.⁷

Craniofacial indices are a reliable source to provide successful results for ethnicity identification as compared to appendicular skeletal remains indices.⁸

Departments of ¹Radiology & Molecular Imaging and ³Human & Clinical Anatomy, ²College of Medicine and Health Sciences, Sultan Qaboos University, Muscat, Oman; ⁴Radiology Residency Program, Oman Medical Specialty Board, Muscat, Oman

*Corresponding Author's e-mail: srinivasa@squ.edu.om

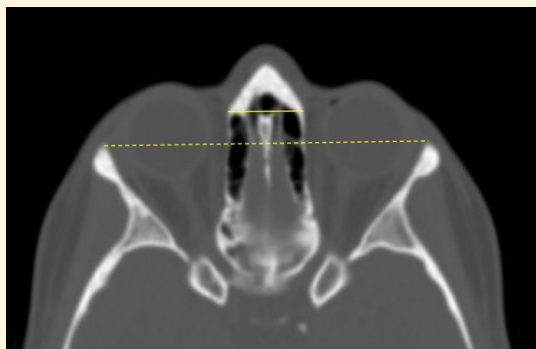


Figure 1: Axial computed tomography image of the orbits in the bone window showing the interorbital distance (short solid line) and interzygomatic distance (long dashed line).

Radiological investigations are frequently used for craniofacial indices where dry bone collection is impossible.⁹ Factors such as gender, age and laterality influences on OI have been reported in the majority of the studied populations.¹⁰⁻¹² The interorbital distance (IOD) is typically used as a diagnostic criterion in evaluating craniofacial anomalies such as hypertelorism, hypotelorism and orbital clefts.^{2,3,13} This parameter is also used to determine the severity of these anomalies and to plan the surgical correction.^{14,15} In addition to the clinical importance, orbital dimensions are frequently used in anthropology and forensic medicine.¹¹ Till date, there are no studies to evaluate the orbital dimensions of the Omani population. Hence, in the present study, the researchers sought to provide the baseline data of OI and IOD of Omani subjects referred for computed tomography (CT) scans at a tertiary care hospital and classify them under one of three predetermined categories.

Methods

In the present study, the adult Omani patients (aged ≥ 18 years) who had visited the Department of

Radiology and Molecular Imaging at the Sultan Qaboos University Hospital, Muscat, Oman, were studied retrospectively using an electronic medical records database (TrakCare Unified Health Information System). All the consecutive patients of either gender aged ≥ 18 years who had been referred for a CT scan of the brain from 1 January 2019 to 31 March 2019 were included. After applying the inclusion and exclusion criteria, there were 273 Omani patients. Patients with orbital fractures and ocular or facial surgery or deformity were excluded. Additionally, scans with motion artifacts or incomplete coverage of the orbits and those performed for non-Omani patients were also excluded from the study sample.

All the CT scans were performed as per the routine standard protocol for non-enhanced CT of the brain using 64 slice multidetector CT (Siemens Sensation 64, Siemens AG, Munich, Germany) with a kilovoltage peak of 120 kV and tube current modulation. The images and measurements were assessed using the Synapse Radiology PACS, Version 5.7.102 (Synapse[®] Enterprise Imaging, Fujifilm Worldwide, Tokyo, Japan).

The measurements were performed using the reconstructed thin slices of 1.2 mm in the bone window. A window width/level of 2000/500 mm was used while screening the images. The following measurements were performed for every subject: the interorbital distance, interzygomatic distance (IZD), horizontal orbital diameter and vertical orbital diameter. First, the orientation of the axial images was adjusted according to the Frankfort horizontal plane, which is defined as the line from the highest point of the opening of the external auditory canal to the lower margin of the orbital rim.¹⁶ After adjusting the axial plane, the IOD was measured as the minimal distance between the medial orbital walls. The IZD was determined as the maximum distance between the anterior aspects of the zygomatic arches [Figure 1].

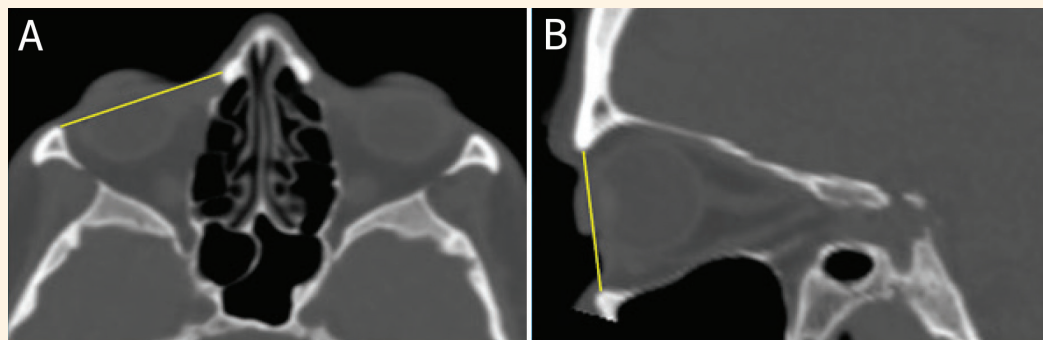


Figure 2: (A) Axial computed tomography image at the level of the orbits showing the horizontal orbital distance of the right orbit (solid line) and (B) a sagittal image showing the vertical orbital distance (solid line).

The horizontal distance of orbit (HDO) was measured as the maximum distance from the anterior lacrimal crest to the lateral orbital wall [Figure 2A]. The vertical distance of orbit (VDO) was performed in the sagittal plane after adjusting the angulation of the sagittal image along the long axis of the orbit and measured as the maximum distance between the frontal and the maxillary bones [Figure 2B]. Finally, OI was calculated using the following formula:

$$OI = VDO/HDO \times 100$$

Statistical Package for the Social Sciences (SPSS), version 23.0 (IBM Corporation, Armonk, New York, USA) was used to analyse the data. The data were presented as mean and standard deviation. Independent sample t-test was used to determine the associations between the orbital dimensions and gender, while paired t-test was used to determine the laterality difference. The association between the orbital dimensions and age groups were determined using one-way analysis of variance (ANOVA). The differences were considered significant at P value <0.05 .

The study was conducted after receiving ethical approval from the Medical Research Ethics Committee at the Sultan Qaboos University Hospital (#SQU-EC/445/2021).

Results

In the present study, 546 orbits from 273 patients were evaluated. There were 136 (49.82%) male and 137 (50.18%) female patients. The mean age of the study subjects was 58.81 ± 19.41 years, with a range of 18–94 years. Only one observer was involved in screening all the 273 subjects' CT scans to measure the orbital dimensions. The mean HDO of the right and left orbits was 39.76 ± 1.75 mm and 39.42 ± 1.66 mm, respectively. The mean VDO of the right and left orbits was 32.83 ± 1.90 mm and 33.01 ± 1.89 mm, respectively.

As described in the methods section, the OI was calculated using the VDO and HDO. The mean OI of the right and left orbits were found to be 82.67 ± 5.36 mm and 83.83 ± 4.93 mm, respectively. A statistically significant association was observed between the right and left orbits with regard to HDO ($P = 0.05$), VDO ($P = 0.003$) and OI ($P = 0.05$) [Table 1]. There was no significant association between gender and OI of both sides of the orbit [Table 2].

There was no significant association between age groups and OI among the study subjects [Tables 3 and 4]. The mean IOD and the mean IZD were found to be

Table 1: Comparison between left and right orbital dimensions of the included Omani patients

Parameter	Mean \pm SD	P value
OI%		
Left orbit	83.83 ± 4.93	0.05
Right orbit	82.67 ± 5.36	
VDO in mm		
Left orbit	33.01 ± 1.89	0.003
Right orbit	32.83 ± 1.90	
HDO in mm		
Left orbit	39.42 ± 1.66	0.05
Right orbit	39.76 ± 1.75	

SD = standard deviation; OI = orbital index; VDO = vertical distance of orbit; HDO = horizontal distance of orbit.

Table 2: Associations of orbital dimensions with respect to gender on the right and left sides of orbit of the Omani patients

Parameter	Mean \pm SD	P value
ROI%		
Female	82.49 ± 4.93	0.59
Male	82.85 ± 5.77	
LOI%		
Female	83.82 ± 4.71	0.99
Male	83.83 ± 5.16	
RVDO in mm		
Female	32.44 ± 1.79	0.001
Male	33.22 ± 1.95	
LVDO in mm		
Female	32.71 ± 1.76	0.01
Male	33.31 ± 1.98	
RHDO in mm		
Female	39.37 ± 1.56	0.001
Male	40.16 ± 1.84	
LHDO in mm		
Female	39.07 ± 1.57	0.001
Male	39.77 ± 1.68	

SD = standard deviation; ROI = right orbital index; LOI = left orbital index; RVDO = right vertical distance of orbit; LVDO = left vertical distance of orbit; RHDO = right horizontal distance of orbit; LHDO = left horizontal distance of orbit.

19.45 ± 1.52 mm and 95.59 ± 4.08 mm, respectively. The mean IOD ($P < 0.05$) and the mean IZD ($P < 0.05$) were significantly higher in males than in females.

Table 3: Comparison between orbital indices of different age groups among included Omani females

Side	Age	Frequency	Mean in % ± SD	P value
Right				
	18–25	5	82.78 ± 5.49	
	26–35	7	82.66 ± 3.60	
	36–45	19	82.49 ± 3.90	
	46–55	20	81.63 ± 5.17	0.93
	56–65	24	81.76 ± 4.36	
	66–75	38	82.85 ± 5.77	
	≥76	24	83.25 ± 5.11	
Left				
	18–25	5	84.06 ± 5.04	
	26–35	7	83.54 ± 3.05	
	36–45	19	83.44 ± 4.43	
	46–55	20	83.9 ± 4.88	0.89
	56–65	24	82.71 ± 3.26	
	66–75	38	84.44 ± 5.13	
	≥76	24	84.17 ± 5.82	

SD = standard deviation.

Discussion

Several radiological and anatomical studies had been conducted to explore the bony dimensions of the orbit.^{4,5,7,10,11,15,17–19} Evidence from these studies report a significant variation among different races and ethnicities. The reporting of reference values of orbital dimensions is clinically important for better diagnosis, surgical approach and outcome, as well as for following-up on various orbital pathologies. The knowledge of orbital dimensions pertaining to each race and ethnic group is also crucial in anthropology and forensic medicine, particularly for identifying and classifying the skull. Despite having tremendous importance, the normative bony dimensions of the orbit were not studied in all populations. To date, the OI of only two populations—Egyptian and Iranian populations—from the Middle-Eastern region have been documented.^{17,19}

The orbital cavity possesses greater height than width and is typically classified into three categories: microseme, mesoseme and megaseme. Previously, studies from different Asian countries, including Japan, China, India, Sri Lanka, Turkey and Iran, have documented the OI of their respective populations and classified them under one of the categories.^{1,4,5} In the present study, the mean OI of Omani subjects was

Table 4: Comparison between orbital indices of different age groups among included Omani males

Side	Age	Frequency	Mean in % ± SD	P value
Right				
	18–25	18	81.61 ± 5.04	
	26–35	14	83.49 ± 6.21	
	36–45	11	80.12 ± 5.20	
	46–55	10	83.52 ± 4.76	0.35
	56–65	16	82.16 ± 4.41	
	66–75	35	84.46 ± 7.26	
	≥76	32	82.55 ± 4.99	
Left				
	18–25	18	83.40 ± 4.79	
	26–35	14	84.07 ± 5.12	
	36–45	11	80.96 ± 5.07	
	46–55	10	79.44 ± 5.33	0.34
	56–65	16	83.64 ± 3.02	
	66–75	35	85.34 ± 5.61	
	≥76	32	83.53 ± 5.57	

SD = standard deviation.

found to be 83.25 ± 4.83 mm and the prevalent orbital type was categorised as mesoseme. The mesoseme orbital class was dominant in the Iranian population as well. Egyptian female subjects also demonstrated mesoseme orbital cavity, but microseme was more prevalent in Egyptian male subjects. In the Turkish population, the megaseme orbital category was observed.¹⁸

In the literature, there are conflicting reports on the sexual dimorphism of OI. In Omani subjects, no significant gender difference in OI was observed (the OI of males was 83.34 ± 5.05, while it was 83.16 ± 4.57 in females). Both genders belonged to the mesoseme category. Similar findings were reported in Brazilian, South Indian subjects and in Kalabaris and Ikwerres of the Rivers ethnic group of Nigeria.^{5,20,21} In contrast, a significant gender difference in OI was found in the Igbos and Urhobos among Nigerian and Ghanaian subjects.⁴ In agreement with these studies, gender differences in bony volume and dimensions were observed even in the Iranian population.¹⁹

Furthermore, the laterality differences with HDO, VDO and OI were statistically significant in Omani subjects. These findings are similar to the study results from the Iranian population.¹⁹ However, contradictory findings of laterality differences were observed in the Indian, Nigerian and Ghanaian populations.^{4,20,22} In the

present study, there were no significant differences in OI among different age groups in both males and females. Similar findings were observed in Ghanaian subjects.⁴ However, in the Malawian and Igbo ethnic groups of Nigerian subjects, the OI was significantly different in different age groups.^{7,22} These discrepancies observed between the studies with regard to orbital dimensions and their associated factors are possibly due to genetic factors.

The IOD is clinically used to diagnose both orbital hypotelorism and hypertelorism. Orbital hypertelorism is distinguished by a longer IOD, most often associated with a variety of craniofacial conditions, including Crouzon syndrome, craniofacial dysplasia and clefts.²³ Hypotelorism is also linked to several conditions, including holoprosencephaly and craniosynostosis.²⁴ Reference values are also important in corrective surgeries involving the above-mentioned craniofacial anomalies. Previous studies have provided the reference values of IOD for different populations. For instance, an IOD of 26.7 and 25.6 mm was observed in American males and females, respectively.¹³ In the Indian population, the reported overall mean IOD was 26.89 mm, while the mean distance was 27.46 mm and 25.93 mm in males and females, respectively.¹ In the present study, the observed IOD values (males: 19.79 ± 1.46; females: 19.12 ± 1.52) were lower than those reported in Indian and American subjects. However, the mean IOD of Omani subjects was close to that of the Iranian population (males: 23 mm; females: 21.7 mm).²⁵ In previous studies, normal interzygomatic distance was observed within the range of 90–109 mm.^{1,26,27} In line with these studies, the IZD in Omani subjects is also found to be within this range.

The variations in orbital dimensions among different populations worldwide could be attributed to the evolutionary processes wherein inheritable mutations can generally occur by natural selection. As a result, population-based differences reflect contemporary environmental pressures, genetic drift, historical and present hybridisation between geographically disparate populations and current selective adaptation of racial diversities to their surroundings.²⁸ In forensic anthropology, human skeletal remains are considered strong evidence for population origin identification and identification of other factors, including gender, age and stature. Therefore, the reference values of orbital dimensions reported in the present study are important in anthropological characterisation. These values are also crucial for the diagnosis and surgical treatment of various orbital pathologies.

The present study has the following limitation. As it is a single-centred study, the study sample may not

be a true representation of the Omani population. A multi-centred study considering the ethnic differences of Omani subjects would be more beneficial to explore.

Conclusion

Results of the present study provide reference values of orbital dimensions in Omani subjects. The prevalent orbital type among the Omani subjects is mesosemia, which is a hallmark of the Caucasian race. Furthermore, these findings may be helpful in the field of forensic medicine and anthropology, as well as for ophthalmologists, neurosurgeons and maxillofacial surgeons.

AUTHORS' CONTRIBUTION

EA, HD and SRS contributed to the study's conception and design. EA, MS, MM and SRS prepared the material and conducted the investigation. MM and SRS performed the formal analysis. EA, SRS and HD collected the data and analysed the results. EA, MS, SRS and HD contributed to the visualisation and presentation of the data. EA, MS, MM and SRS drafted the original manuscript. All authors approved the final version of the manuscript.

CONFLICT OF INTEREST

The authors declare no conflicts of interest.

FUNDING

No funding was received for this study.

References

- Gupta V, Prabhakar A, Yadav M, Khandelwal N. Computed tomography imaging-based normative orbital measurement in Indian population. *Indian J Ophthalmol* 2019; 67:659–63. https://doi.org/10.4103/ijo.IJO_1187_18.
- Converse JM, McCarthy JG, Wood-Smith D. Reconstructive plastic surgery for orbital hypertelorism. In: Converse JM, McCarthy JG, Wood-Smith D, eds. *Symposium on Diagnosis and Treatment of Craniofacial Anomalies*, 20th vol. London, UK: Mosby. 1979. pp. 207–21.
- Mafee ME, Valvassori GE. Radiology of the craniofacial anomalies. *Otolaryngol Clin North Am* 1981; 14:939–88.
- Botwe BO, Sule DS, Ismael AM. Radiologic evaluation of orbital index among Ghanaians using CT scan. *J Physiol Anthropol* 2017; 36:29. <https://doi.org/10.1186/s40101-017-0145-7>.
- Fernandes LC, Rabello PM, Santiago BM, Carvalho MV, Sena Junior MR, Soriano EP, et al. Craniometric study of the orbital index in Brazilian skulls. *RGO-Revista Gaucha de Odontologia* 2021; 19:69. <https://doi.org/10.1590/1981-86372021001320190115>.
- Husmann PR, Samson DR. In the eye of the beholder: Sex and race estimation using the human orbital aperture. *J Forensic Sci* 2011; 56:1424–9. <https://doi.org/10.1111/j.1556-4029.2011.01864.x>.

7. Igbigbi PS, Ebite LE. Orbital index of adult Malawians. *Anil Agrawal's Internet J Forensic Med Toxicol* 2010; 11:1.
8. Giles E, Elliot O. Race identification from cranial measurements. *J Forensic Sci* 1962; 2:147–57.
9. Iscan M. Forensic anthropology of sex and body size. *Forensic Sci Int* 2005; 147:107–12. <https://doi.org/10.1016/j.foresciint.2004.09.069>.
10. Mehta M, Saini V, Nath S, Patel MN, Menon SK. CT scan images to determine the origin from craniofacial indices for Gujarati population. *J Forensic Radiol Imaging* 2014; 2:64–71. <https://doi.org/10.1016/j.jofri.2014.02.001>.
11. Xing S, Gibbon V, Clarke R, Liu W. Geometric morphometric analyses of orbit shape in Asian, African, and European human populations. *Anthropol Sci* 2012; 120803. <https://doi.org/10.1537/ase.120803>.
12. Ebeye A, Otikpo O. Orbital index in Urhobos of Nigeria. *IOSR J Dent Med Sci* 2013; 2:51–3. <https://doi.org/10.9790/0853-0825153>.
13. Mafee MF, Pruzansky S, Corrales MM, Phatak MG, Valvassori GE, Dobben GD, et al. CT in the evaluation of the orbit and the bony interorbital distance. *AJNR Am J Neuroradiol* 1986; 7:265–9.
14. Sirimaharaj W, Kanpuan W, Angkurawaranon S. The relationship between external bony defects and widened lateral interorbital distance in frontoethmoidal encephalomeningocele. *J Craniomaxillofac Surg* 2019; 47:1563–8. <https://doi.org/10.1016/j.jcms.2019.07.013>.
15. Chatdokmaiprai C, Kiranantawat K, Lertsithichai P, Taeshineetanakul P. Normative data of the interorbital distance in Thai population. *J Craniofac Surg* 2018; 29:1939–44. <https://doi.org/10.1097/SCS.0000000000005050>.
16. Jullabussapa N, Khwanngern K, Pateekhum C, Angkurawaranon C, Angkurawaranon S. CT-based measurements of facial parameters of healthy children and adolescents in Thailand. *AJNR Am J Neuroradiol* 2020; 41:1937–42. <https://doi.org/10.3174/ajnr.A6731>.
17. Fetouh FA, Mandour D. Morphometric analysis of the orbit in adult Egyptian skulls and its surgical relevance. *Eur J Anat* 2014; 4:303–15.
18. Ozdikici M, Bulut E, Agca S. Assessment of the orbital structures using computed tomography in healthy adults. *Niger J Clin Pract* 2021; 24:561–8. https://doi.org/10.4103/njcp.njcp_77_20.
19. Khademi Z, Bayat P. Computed tomographic measurements of orbital entrance dimensions in relation to age and gender in a sample of healthy Iranian population. *J Curr Ophthalmol* 2016; 28:81–4. <https://doi.org/10.1016/j.joco.2016.03.002>.
20. Mekala D, Shubha R, Rohini M. Orbital dimensions and orbital index: A measurement study on South Indian dry skull. *Int J Anatomy Res* 2015; 3:1387–91.
21. Leko Bankole J, Douglas P, Ukoima HS, Madugba C. Radiological assessment of orbital dimensions of the Kalabaris and Ikwerres of Rivers State, Nigeria. *Afr J Biomed Res* 2012; 15:197–200.
22. Ezeuko V, Om'Iniabohs F. Radiologic evaluation of orbital index among the Igbo ethnic group. *Eur J Anatomy* 2015; 1:9–14.
23. Sharma RK. Hypertelorism. *Indian J Plast Surg* 2014; 47:284–92. <https://doi.org/10.4103/0970-0358.146572>.
24. Mirsky D, Feygin T. Imaging of fetal orbits. *J Pediatr Neuroradiol* 2015; 4:070–81.
25. Bayani L. The bony interorbital distance and orbital measurements in the Iranian population: A CT study. *Iran J Radiol* 2006; 3:e79012.
26. Ozgen A, Ariyurek M. Normative measurements of orbital structures using CT. *AJR Am J Roentgenol* 1998; 170:1093–6. <https://doi.org/10.2214/ajr.170.4.9530066>.
27. Lee JS, Lim DW, Lee SH, Oum BS, Kim HJ, Lee HJ. Normative measurements of Korean orbital structures revealed by computerized tomography. *Acta Ophthalmol Scand* 2001; 79:197–200. <https://doi.org/10.1034/j.1600-0420.2001.079002197.x>.
28. Catalina-Herrera CJ. Morphometric study of the orbit's base in male and female skulls of Spaniards. *Bull Assoc Anat (Nancy)* 1988; 72:5–7.