

Large Intraosseous Haemangioma of the Sacral Vertebra

The radiological imaging findings

NerbadySwari Deep,¹*Sudipta Mohakud,¹ Mantu Jain,² Suprava Naik,¹ Manas Baisakh³

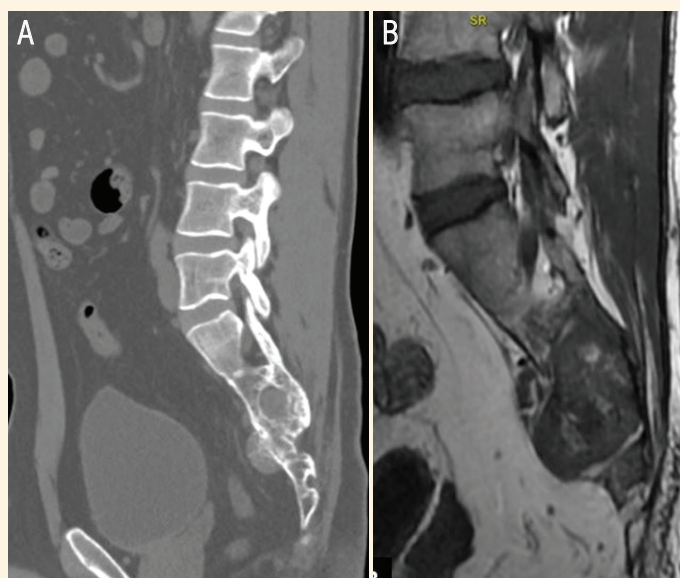


Figure 1: Imaging scans of the spine of a 28-year-old male. **A:** Sagittal computed tomography bone window image showing an expansile soft tissue density lytic lesion involving the S2 to S5 sacral vertebrae with a presacral bulge and extension into sacral foramina. **B:** Sagittal T1-weighted image showing a well-margined expansile, predominantly hypointense lesion involving the S2 to S5 vertebrae.

A 28-YEAR-OLD MALE TECHNOLOGIST presented to the orthopedics department of the All India Institute of Medical Sciences, Bhubaneswar, India, in 2020 with a complaint of dull aching low back pain on prolonged sitting for a period of six months. There was local tenderness in the sacral region on deep palpation without local swelling or pain radiation to the limbs. The straight leg raising test was negative. He was intact neurologically (American Spinal Injury Association grade E) and his pain score was low (visual analogue scale = 2/10). An X-ray showed a suspicious lytic lesion in the sacral vertebra. He underwent a computed tomography (CT) scan and a contrast-enhanced magnetic resonance imaging (MRI) to characterise the lesion further. The CT scan highlighted a large expansile lucent lesion associated with a soft tissue component involving the S2 to S5 vertebrae producing a presacral bulge and extension into bilateral sacral *foramina* [Figure 1A]. The lesion

had internal bony septations with preserved vertebral height and bony outline. The MRI showed an expansile well-margined T1 hypointense and T2 hyperintense lesion, which was hyperintense in the short tau inversion recovery sequence (STIR) [Figure 1B]. Post-gadolinium injection T1 fat-suppressed images showed avid homogeneous lesion enhancement [Figure 2]. The imaging findings were suggestive of a benign lesion, most likely vertebral body haemangioma (VBH).

A biopsy was planned to exclude malignancy as there was a presacral soft-tissue bulge. The histopathological study revealed readily recognisable vascular structures with red blood cells or transudate, lined by a monolayer of endothelial cells characteristic of haemangioma [Figure 3]. The patient was managed conservatively with yearly follow-up; there was no interval change in the lesion's size on follow-up MRI.

Informed consent was obtained from the patient to use his medical data for publication purposes.

Departments of ¹Radiodiagnosis and ²Orthopedics, All India Institute of Medical Sciences, Bhubaneswar, India; ³Department of Pathology, Prolife Diagnostic, Bhubaneswar, India

*Corresponding Author's e-mail: drsudipta.m@gmail.com

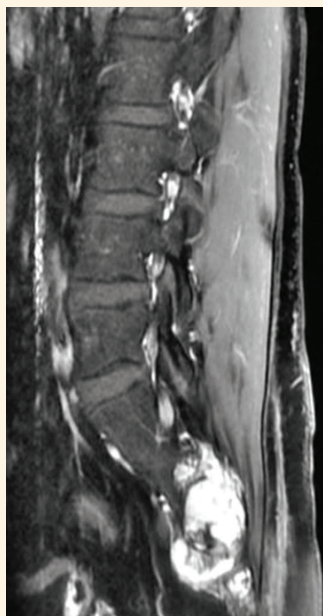


Figure 2: Sagittal post-intravenous gadolinium injection T1 fat-suppressed image showing avid enhancement of the lesion with a presacral bulge, extension into the sacral foramen and spinal canal.

Comment

VBH occurs in more than 11% of the population, yet sacral involvement is uncommon. VBH are seen in adults with a male-to-female ratio of 1:1.5.¹ They are indolent except in <1% when they become symptomatic either by bone expansion with or without an associated pathological fracture, extension into the neural foramen, or the spinal canal causing radiculopathy or myelopathy and are known as aggressive haemangiomas.^{2,3} Aggressive haemangiomas present with pain and they may have an extraosseous soft tissue component contiguous with the osseous lesion.

The differential diagnoses are chordoma, giant cell tumours, enchondroma, chondrosarcoma, aneurysmal bone cyst, metastases and rarely hydatid cysts in endemic areas.^{1,4,5}

A haemangioma is well-defined with a hyperintense signal on T1-weighted imaging (T1WI) and T2WI due to the fat content and avid homogeneous enhancement on post-contrast imaging. The vascular elements make the signal high on fluid-sensitive sequences. The thickened vertical trabeculae are more appreciated on the CT scans producing the 'polka dot sign'. Sometimes atypical presentation occurs due to variable amount of fat and vascular components producing an atypical hypo- to iso-intense signal on T1WI and heterogeneous hyperintensity on T2WI and STIR sequences.²

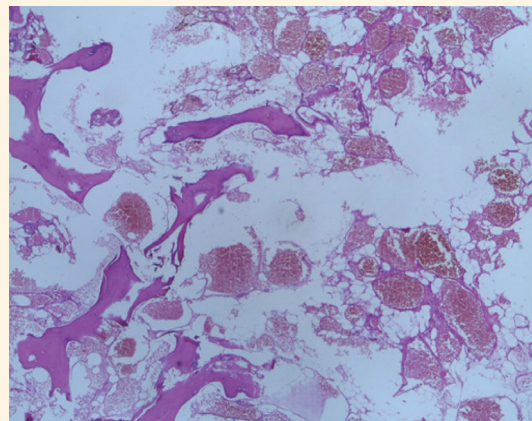


Figure 3: Haematoxylin and eosin stain of the biopsy specimen of the sacral lesion at $\times 4$ magnification showing variable-sized blood-filled vascular spaces between mature bony trabeculae, lined by a monolayer of endothelial cells.

Sacral haemangiomas do not require any treatment until they become painful or encroach the sacral nerves.

This case highlights the presence of a presacral soft tissue component in a haemangioma mimicking a malignant lesion. Accurate identification of imaging findings can reduce patient anxiety and morbidity due to appropriate surgical intervention.

AUTHORS' CONTRIBUTION

ND, SN and MB were involved in diagnosis, manuscript editing and reviewing the manuscript. SM and MJ were involved in data collection, drafting, editing and reviewing the manuscript. All authors approved the final version of the manuscript.

References

1. Vanheule E, Huysse W, Herregods N, Verstraete K, Jans L. Sacral Tumours on MRI: A pictorial essay. *J Belg Soc Radiol* 2019; 103:62. <https://doi.org/10.5334/jbsr.1887>.
2. Gaudino S, Martucci M, Colantonio R, Lozupone E, Visconti E, Leone A, et al. A systematic approach to vertebral hemangioma. *Skeletal Radiol* 2015; 44:25–36. <https://doi.org/10.1007/s00256-014-2035-y>.
3. Wang B, Zhang L, Yang S, Han S, Jiang L, Wei F, et al. Atypical radiographic features of aggressive vertebral hemangiomas. *J Bone Joint Surg Am* 2019; 101:979–86. <https://doi.org/10.2106/JBJS.18.00746>.
4. Thornton E, Krajewski KM, O'Regan KN, Giardino AA, Jagannathan JP, Ramaiya N. Imaging features of primary and secondary malignant tumours of the sacrum. *Br J Radiol* 2012; 85:279–86. <https://doi.org/10.1259/bjr/25247602>.
5. Mohakud S, Ray B, Naik S, Deep N. Isolated sacral vertebral hydatid cyst presenting with pathological fracture. *J Neurosci Rural Pract* 2019; 10:565–6. <https://doi.org/10.1055/s-0039-1695700>.