

Successful Management of Rhino-Orbital-Cerebral Mucormycosis in a Child with Acute-on-Chronic Kidney Disease and Malnutrition

Case report and literature review

*Mohammed Al Reesi,¹ Taleb Al Muqbali,² Ahmed Al Ajmi,³ Varna Menon⁴

ABSTRACT: Mucormycosis is a very rare fungal infection in children. It is caused by opportunistic fungi and mainly affects immunocompromised patients. Early diagnosis is very important for a good outcome. Successful management requires the reversal of the underlying predisposing risk factors, surgical debridement and prompt administration of active antifungal agents, with liposomal amphotericin B being the first-line therapy. This case, to the best of the authors' knowledge, is the first rhino-orbital-cerebral mucormycosis to be reported on among Omani children. We highlight the importance of early diagnosis and prompt surgical and medical interventions in achieving a satisfactory outcome and review the published literature in regard to the management.

Keywords: Mucormycosis; Sinusitis; Proptosis; Liposomal amphotericin B; Rhizopus; Posaconazole; Malnutrition; Oman.

MUCORMYCOSIS IS A VERY RARE FUNGAL infection in children. It is caused by opportunistic fungi and mainly affects immunocompromised patients.¹ Early diagnosis is very important for a good outcome.² Successful management requires the reversal of the underlying predisposing risk factors, surgical debridement and prompt administration of active antifungal agents, with liposomal amphotericin B being the first-line therapy.^{3,4} This case, to the best of the authors' knowledge, is the first rhino-orbital-cerebral mucormycosis to be reported on among Omani children. This report highlights the importance of early diagnosis and prompt surgical and medical interventions in achieving a satisfactory outcome and reviews the published literature in regard to the management.

Case report

A six-year-old Omani girl was referred to a tertiary care hospital in Oman from a local health centre in 2016 with sudden onset facial swelling, left periorbital skin rash and reduced oral intake for one day. She had no history of fever, nasal congestion, ear pain or toothache. There was no history of allergy, preceding trauma or insect bites. She was not a diabetic and had no history of haematological malignancy or recurrent infections. She was operated on for meningomyelocele

in the neonatal period. That was complicated by reflux nephropathy, chronic kidney disease and paraplegia. She had normal speech, vision and hearing.

The patient was very thin and weighed just 9 kg. She was tachypneic with acidotic breathing and she had a respiratory rate of 40 per minute, a pulse rate of 120 beats per minutes, and blood pressure (BP) of 100/80 mmHg, SpO₂ of 100% with 10 L of O₂ via non-rebreathing mask. She had mild proptosis of the left eye, left-sided facial swelling of the left orbit with multiple pustular lesions on the left eye brow, left side of forehead and nasal bridge [Figure 1]. She was not able to see from her left eye, but she had a normal ocular motility and fundus. An oral cavity examination showed multiple dental caries. Her left palatal mucosa was coated by a very thick white lesion opposite her upper first and second left molars, measuring 2 × 2 cm and with central dark discoloration [Figure 2A]. Neurologically, she was conscious and oriented. She was hypotonic in both upper and lower limbs with brisk reflexes (her baseline). Other systemic examinations were unremarkable.

An initial laboratory investigation showed a haemoglobin of 6.84 g/dL, a white blood cell count of 38.80×10^3 with mainly neutrophils (35.35×10^3) and platelets count of 1078.00×10^3 . Her C-reactive protein was very high (342 mg/L). Her venous blood gas showed metabolic acidosis with bicarbonate of 7.8 nmol/L and base excess of -22 mmol/L. She had acute-

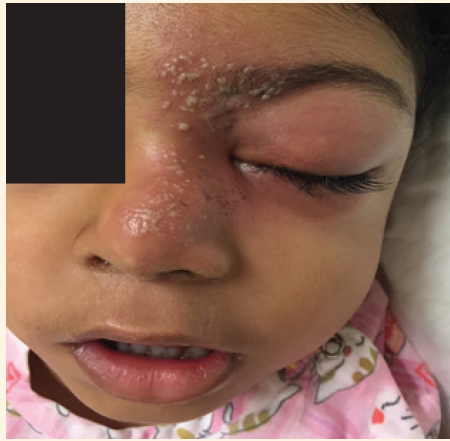

Figure 1: Photograph showing mild proptosis, swelling and redness of the left eye and multiple pustular lesions on the left eyebrow, left side of the forehead and nasal bridge.

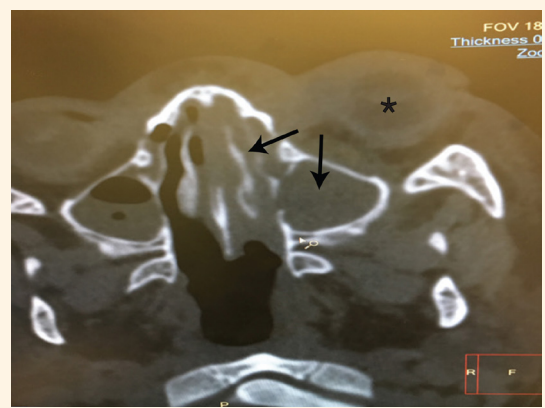


Figure 3: Axial computed tomography orbit showing left eye proptosis (star), maxillary and ethmoid sinusitis (arrows) with subtle rarefaction of the left *lamina papyracea*.

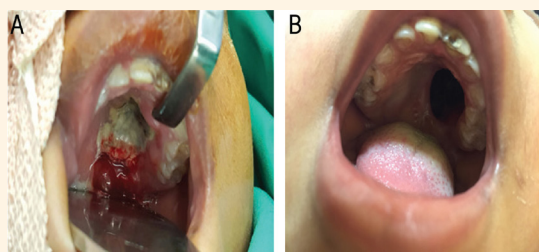


Figure 2: A: Photograph showing very thick white lesion coating the hard palate with central dark discoloration, measuring 2 × 2 cm. B: The oral cavity on follow-up showing healthy and clear margin of the lesion.

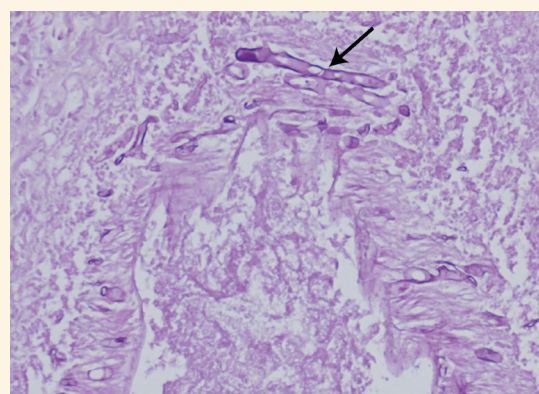


Figure 4: Section of nasal biopsy at ×200 magnification showing blood vessel invasion by periodic acid-Schiff stain, positive non-septate, broad, ribbon-like fungal hyphae (arrow).

on-chronic kidney disease. Her urea was 22.6 mmol/L, her creatinine was 150.66 µmol/L, while other electrolytes were within normal limits. Her random blood glucose was 6.27 mmol/L and glycosylated haemoglobin was 4.42%. Her chest radiograph was normal.

She was initially admitted into the general paediatric ward and a diagnosis of periorbital cellulitis was made. A few hours later, she was shifted to a paediatric intensive care unit after she developed hypotension (blood pressure = 48/40 mmHg), which was corrected by two boluses of normal saline. A bicarbonate infusion was also given to correct her metabolic acidosis. She was given cefotaxime, amikacin, metronidazole and cloxacillin intravenously. Contrasted computed tomography (CT) of the orbits and brain revealed pan maxillary and ethmoid sinusitis (more on the left side) with subtle rarefaction of the left *lamina papyracea*. There was an inflammatory phlegmon of the medial and inferior wall of the left orbit measuring 28 × 7 mm. There was no evidence of bone destruction or intracranial involvement [Figure 3]. Multidisciplinary teams (MDTs) were consulted urgently, including paediatric infectious diseases, ophthalmology, oral maxillofacial surgery

(OMFS) and ear, nose and throat (ENT) teams. The antimicrobial regimen was changed to renal-adjusted doses of intravenous ceftazidime, clindamycin and ciprofloxacin to cover the most likely causative organisms, including *staphylococcus aureus*, anaerobes and *Pseudomonas aeruginosa*. In addition, an invasive fungal infection, such as mucormycosis, was strongly suspected. Therefore, a diagnostic nasal endoscopy was performed within 24 hours of her being admitted, which showed necrosis of the left maxillary wall and upper part of the left inferior turbinate. Urgent KOH staining of the biopsy specimen showed aseptated cylindrical fungal hyphae. Subsequently, liposomal amphotericin B (AmBisome) was administered empirically at a dose of 5 mg/kg/dose, once daily within 48 hours of admission. The histopathology showed necrotic tissue containing aseptated, broad fungal hyphae, displaying right angled branching with angio-invasion and thrombosis of the blood vessels, highly suggestive of mucormycosis [Figure 4]. The culture of the initial swab confirmed the growth of *Rhizopus spp.*

The patient underwent a debridement of the left nasal cavity, an inferior turbinectomy, medial maxillectomy and ethmoidotomy. Unfortunately, she developed skin necrosis in the medial aspect of the left eye two days after the operation. Intraorally, the left palatal region had the appearance of decreased vitality and bone necrosis was suspected. Repeated CT demonstrated that the left orbital phlegmon had extended up to the orbital apex, transformed into an abscess and increased in size to 31 × 10 mm. The optic nerve had thickened. However, there was no intracranial abnormal enhancement and dural sinuses were normal. A left orbital exenteration was discussed, but the parents were reluctant to give consent. She underwent left palatectomy, maxillectomy and debridement on the 10th day after her admission. There was no drainable pus from the orbital abscess site. Despite this, she still had left orbital proptosis and increasing periorbital ecchymosis one week after the second operation. Therefore, magnetic resonance imaging (MRI) with contrast was done to further delineate the anatomy and extension. That showed left ethmoid opacification, abnormal enhancement of the left septal/preseptal area with extension to retro-orbital space and a small abscess formation in the left orbit, measuring 1.9 × 0.8 cm with mass effect causing optic nerve deviation and proptosis. It also revealed abnormal enhancement of the cavernous sinus, but no brain parenchyma extension. Lumbar puncture could not be done because she was not stable enough for the procedure. The addition of oral posaconazole was planned but she was not able to tolerate it orally. Instead, caspofungin was added to AmBisome on 17th day of admission due to an unsatisfactory response and ceftriaxone was commenced to address any secondary bacterial central nervous system infection. Furthermore, ethmoid sinus debridement was done and her left orbitotomy did not reveal any pus.

Only after her third operation did the clinical signs start to gradually improve. She started to see a little from her left eye and was able to count fingers with difficulty. But there was no further improvement as the disease progressed. Trans-orally, her inferior maxillectomy site was healing well with good re-epithelialisation. She was able to take some medicine and food orally after using a resin obturator to cover the post-operative palatal defect. Eventually, the histopathology from the third operation did not show any fungal elements and the culture was negative; 24 days after admission, her creatinine started to improve to 104 µmol/L after a period of fluctuation. Subsequently, her AmBisome dose was gradually increased to 9 mg/kg/day. She was screened for immunodeficiency: she was not lymphopenic, her HIV

serology was non-reactive, immunoglobulin levels and lymphocyte subset were normal. An ultrasound of her abdomen did not reveal any abscesses. After eight weeks of AmBisome and four weeks of caspofungin, she was discharged home and her therapy was transitioned to oral posaconazole at a dose of 17 mg/kg/day in three divided doses. That was continued for three months whereupon a follow-up-MRI showed a complete resolution of the abscesses in the left orbital region and left maxillary sinus. She was followed-up regularly in the clinics by a multidisciplinary team. All her clinical signs improved with no relapse of infection to date [Figure 2B]. The patient's mother has given written consent to publish this case and its related images.

Discussion

Mucormycosis is a rare, aggressive, angio-invasive and highly destructive fungal infection with very high morbidity and mortality.^{1,2,4} It is caused by ubiquitous fungi, predominantly belonging to the order Mucorales.⁵ The *Rhizopus* species, the causative agent in our patient, is responsible for approximately one third of mucormycosis cases overall and accounts for 85% of rhino-cerebral cases.^{2,6,7} The most important predisposing factors for mucormycosis are malignancies and poorly controlled diabetes mellitus.¹⁻⁹ Other predisposing factors include chronic kidney disease and malnutrition, both of which were present in the current case.¹ Recently, increasing mucormycosis cases were also identified worldwide in people with coronavirus disease 2019 (COVID-19), particularly more in those with pre-existing diabetes mellitus and corticosteroids use.⁸

Rhino-cerebral mucormycosis has been associated with acute and chronic kidney disease with fatal outcome. Altered immune status, leukopenia and metabolic acidosis in those patients may be a plausible mechanism of predisposition.¹⁰ As a risk factor, malnourishment in children is mainly associated with gastrointestinal mucormycosis.¹ There was no clinical or radiological evidence of abdominal organ involvement in the current case. In addition, her investigations were negative for diabetes mellitus and immunodeficiency.

The successful management of mucormycosis requires early diagnosis, reversal of underlying predisposing risk factors, prompt administration of active antifungal agents and aggressive surgical debridement.^{3,4} Due to a lack of awareness of risk factors and nonspecific clinical and radiologic findings, many cases are not diagnosed for many weeks after the time of presentation.^{3,4} Histopathology and fungal culture

are considered the gold standard for the diagnosis.^{4,7,11} Mucorales are readily recognised morphologically on the basis of non-septate or occasionally pauci-septate, broad, thin walled hyphae with wide angled branching and evidence of angioinvasion.^{3,9,11} We believe that the early diagnosis achieved within 24 hours of patient's admission played a very important role in her satisfactory outcome.

Mucorales are resistant to most antifungals, except amphotericin B-deoxycholate (including lipid formulations of amphotericin B, AmBisome) and the new triazole posaconazole.⁵ While liposomal amphotericin B is the recommended first-line therapy, posaconazole is mainly used as a stepdown or salvage therapy.^{3,4,11,12} Chamilos *et al.* showed that delayed amphotericin B therapy (≥ 6 days after diagnosis) was associated with a two-fold increase in mortality in patients with haematological malignancy and mucormycosis compared with early treatment (83% versus 49%).⁵ Ray *et al.* reported a case of rhino-orbital mucormycosis in a child with acute kidney injury. Amphotericin B was started two weeks after admission. Although some clinical response was noticed, the child died of massive gastrointestinal hemorrhage.¹⁰ The response rate to liposomal amphotericin B ranges between 23–58%.¹² The optimal dose is not known, but most experts recommend a daily dose of 5–7.5 mg/kg/day. Although higher doses can lead to nephrotoxicity, doses up to 10 mg/kg/day are recommended for disseminated diseases and are well-tolerated in children.^{4,6,10,13}

On the contrary, the use of amphotericin B-deoxycholate is limited by its substantial nephrotoxicity, specifically in the doses and treatment duration needed for mucormycosis.⁹ liposomal amphotericin B was commenced in the current case within 48 hours of admission. She tolerated increasing the dose to 9 mg/kg/dose once daily without worsening her renal parameters. Posaconazole has an overall success rate of 60–70% when used as a salvage agent.¹⁴ A dose between 17 and 24 mg/kg/day is suggested in order to achieve target plasma concentration.¹⁵ The addition of oral posaconazole as a salvage therapy was postponed in our case till the day of discharge because she was not able to tolerate it after the operation. Despite the late administration, the current patient showed a good response to it on follow-up. Echinocandins are not recommended because they have a modest effect against Mucorales *in vivo* and virtually no activity *in vitro*.^{10,16} However, some reports suggested its use based on the theory that *Rhizopus oryzae*, expresses the target enzyme for echinocandins (1,3-b-glucan synthase). In a small retrospective study, Caitlin *et al.*

reported a superior success rate in patients with rhino-orbital-cerebral mucormycosis who received polyene-caspofungin therapy compared to patients treated with polyene monotherapy.¹⁵ Caspofungin was added to the current case because of the progressive disease whilst on liposomal amphotericin B therapy and an inability to tolerate oral posaconazole initially.

Our patient started to improve after the third operation, which coincided with initiation of caspofungin. Stronger evidence is needed, however, before recommending this agent for the treatment of mucormycosis.⁹ Our patient received antifungal therapy for approximately five months. The reported length of treatment ranged between 3–36 months. This should be guided by the clinical and radiological response.^{6,9}

De-bulking the infection by early aggressive surgical debridement is a very important and critical component of therapy. Multiple surgeries may be required in the case of extensive disease.¹¹ Pana *et al.* has demonstrated less mortality in patient given combined antifungals and surgery compared to those given antifungals alone (18.5% versus 60%).¹⁷ Our patient required three sessions of complex operations, without which, it was clear that pharmaceutical interventions were not sufficient to control the infection.

Conclusion

We described the successful management of severe rhino-orbital-cerebral mucormycosis in an Omani child. Despite a very high mortality, early diagnosis and prompt medical and surgical interventions were the key factors in achieving a good outcome in this case. Keeping a high index of suspicion and raising the awareness about this aggressive infection and its predisposing factors among all clinicians dealing with immunocompromised paediatric patients, is of paramount importance for early recognition and prompt management.

AUTHORS' CONTRIBUTION

MAR prepared, drafted and reviewed the manuscript. TAM, AAA and VM contributed to drafting and reviewing the manuscript. All authors read and approved the final manuscript.

References

1. Binder U, Maurer E and Lass-Flörl C. Mucormycosis – from the pathogens to the disease. *Clin Microbiol Infect* 2014; 20: 60–6. <https://doi.org/10.1111/1469-0691.12566>.

2. Petrikkos G, Skiada A, Drogari-Apiranthitou M. Epidemiology of mucormycosis in Europe. *Clin Microbiol Infect* 2014; 20:67–73. <https://doi.org/10.1111/1469-0691.12563>.
3. Katragkou A, Walsh TJ, Roilides E. Why is mucormycosis more difficult to cure than more common mycoses? *Clin Microbiol Infect* 2014; 20:74–81. <https://doi.org/10.1111/1469-0691.12466>.
4. Skiada A, Lass-Floerl C, Klimko N, Ibrahim A, Roilides E, Petrikkos G. Challenges in the diagnosis and treatment of mucormycosis. *Med Mycol* 2018; 56:93–101. <https://doi.org/10.1093/mmy/myx101>.
5. Chamilos G, Lewis RE, Kontoyiannis DP. Delaying amphotericin B-based frontline therapy significantly increases mortality among patients with hematologic malignancy who have zygomycosis. *Clin Infect Dis* 2008; 47:503–9. <https://doi.org/10.1086/590004>.
6. Muggeo P, Calore E, Decembrino N, Frenos S, De Leonardi E, Colombini A, et al. Invasive mucormycosis in children with cancer: A retrospective study from the Infection Working Group of Italian Pediatric Hematology Oncology Association. *Mycoses* 2019; 62:165–70. <https://doi.org/10.1111/myc.12862>.
7. Jeong W, Keighley C, Wolfe R, Lee WL, Slavin MA, Kong DCM, et al. The epidemiology and clinical manifestations of mucormycosis: A systematic review and meta-analysis of case reports. *Clin Microbiol Infect* 2019; 25:26–34. <https://doi.org/10.1016/j.cmi.2018.07.011>.
8. Singh AK, Singh R, Joshi SR, Misra A. Mucormycosis in COVID-19: A systematic review of cases reported worldwide and in India. *Diabetes Metab Syndr* 2021; 15:102146. <https://doi.org/10.1016/j.dsx.2021.05.019>.
9. Cornely OA, Alastruey-Izquierdo A, Arenz D, Chen SCA, Dannaoui E, Hochhegger B, et al; Mucormycosis ECMM MSG Global Guideline Writing Group. Global guideline for the diagnosis and management of mucormycosis: An initiative of the European Confederation of Medical Mycology in cooperation with the Mycoses Study Group Education and Research Consortium. *Lancet Infect Dis* 2019; 19:e405–21. [https://doi.org/10.1016/S1473-3099\(19\)30312-3](https://doi.org/10.1016/S1473-3099(19)30312-3).
10. Ray MS, Kumar V, Jain D, Dubey NK. Rhino-orbital mucormycosis in acute renal failure. *Indian Pediatr* 2002; 39:381–5.
11. Srinivas R, Jacob TJK, Raj PM, Korula S, Mathew LG. Paediatric mucormycosis: tailoring surgical strategies to compliment anti-fungal chemotherapy. Different strokes for different folks. *Trop Doct* 2020; 50:87–90. <https://doi.org/10.1177/0049475519874270>.
12. Lanternier F, Dannaoui E, Morizot G, Elie C, Garcia-Hermoso D, Huerre M, et al; French Mycosis Study Group. A global analysis of mucormycosis in France: The RetroZygo Study (2005–2007). *Clin Infect Dis* 2012; 54:S35–43. <https://doi.org/10.1093/cid/cir880>.
13. Lewis RE, Lortholary O, Spellberg B, Roilides E, Kontoyiannis DP, Walsh TJ. How Does Antifungal Pharmacology Differ for Mucormycosis Versus Aspergillosis? *Clin Infect Dis* 2012; 54:S67–72. <https://doi.org/10.1093/cid/cir884>.
14. Zaoutis TE, Roilides E, Chiou CC, Buchanan WL, Knudsen TA, Sarkisova TA, et al. Zygomycosis in children: A systematic review and analysis of reported cases. *Pediatr Infect Dis J* 2007; 26:723–7. <https://doi.org/10.1097/INF.0b013e318062115c>.
15. Ojeda-Diezbarroso K, Aguilar-Rascón J, Jiménez-Juárez RN, Moreno-Espinosa S, Reséndiz-Sánchez J, Romero-Zamora JL. Successful posaconazole salvage therapy for rhinocerebral mucormycosis in a child with leukemia. Review of the literature. *Rev Iberoam Micol* 2019; 36:160–4. <https://doi.org/10.1016/j.riam.2018.07.008>.
16. Reed C, Bryant R, Ibrahim AS, Edwards J Jr, Filler SG, Goldberg R, et al. Combination polyene-caspofungin treatment of rhino-orbital-cerebral mucormycosis. *Clin Infect Dis* 2008; 47:364–71. <https://doi.org/10.1086/589857>.
17. Pana ZD, Seidel D, Skiada A, Groll AH, Petrikkos G, Cornely OA, et al; Collaborators of Zygomycosis.net and/or FungiScope™ Registries*. Invasive mucormycosis in children: an epidemiologic study in European and non-European countries based on two registries. *BMC Infect Dis* 2016; 16:667. <https://doi.org/10.1186/s12879-016-2005-1>.